



# Hemothorax Occurring After Central Venous Catheter Removal: A Case Report

Jony E. Dib, MD<sup>1</sup>, Rim A. Boutari, MD<sup>2</sup>, Boshra A. Yaacoub, MD<sup>2</sup>, Nayef A. Al Khalil, MD<sup>2</sup>, Mohamad A. Al Ayoubi, MD<sup>2</sup>, Othman S. Itani, MD<sup>3</sup>

<sup>1</sup>Pulmonary and Critical Care Department, Lebanese University, Beirut, Lebanon

<sup>2</sup> Internal Medicine Department, Lebanese University, Beirut, Lebanon

<sup>3</sup> Pulmonary and Critical Care Specialist, Rafic Hariri University Hospital, Beirut, Lebanon

Corresponding Author : Jony E. Dib. Lebanon, Baadba, Hadath. [dr.jonydib@gmail.com](mailto:dr.jonydib@gmail.com). Rafic Hariri University Hospital, Beirut, Lebanon.

doi: <https://doi.org/10.38179/ijcr.v3i1.123>

## Abstract

**Background:** Central venous catheterizations are used frequently in critical care unit. The procedure is associated with various complications ranging from mechanical ones during insertion and the possibility of vessel laceration and dissection to infections, not to forget haemothorax and pneumothorax that may require chest tube insertion. However, some complications may also origin from its removal.

**Case Report:** This is a case of a 72-year-old patient with multiple comorbidities admitted to the Intensive Care Unit (ICU) for respiratory distress. A central line was inserted because a peripheral line was hard to establish, and as a consequence of catheter removal, he had a massive right-sided hemothorax.

**Conclusion:** Central venous line removal could cause fatal complications such as massive hemothorax that should be looked for. We emphasize monitoring of patients after catheter removal because the uncommon nature of this complication can lead to diagnosis delay and even misdiagnosis.

**Keywords:** Case report, Complication, Central line, Central venous catheter, Hemothorax

Received: 2021.07.17  
Accepted: 2021.11.11  
Published: 2022.06.04

**Financial support:** None  
**Conflict of interest:** None  
**Patient Consent:** Written consent was obtained from the patient for the publication of this case and accompanying images.

## Introduction

Central venous catheterization, first described in 1952, is a technique used for several indications such as the need for fluid resuscitation, blood transfusion, drug infusion, hemodynamic monitoring and to establish safe and large bore access for patients with difficulty inserting a peripheral intravenous (IV) access [1]. Potential complications of this procedure include insertion site pain or hematoma, misplacement, infection, vessel laceration or dissection, thrombosis, and pneumothorax that may require chest tube insertion [2-4]. However, some complications may be caused by its removal mainly air embolism, catheter fracture embolism, dislodgement of thrombus or fibrin sheath, and bleeding [5].

Hemothorax is the accumulation of blood in the pleural space or a pleural fluid hematocrit (Hct) of greater than 50%. Although the major cause is thoracic trauma, spontaneous, iatrogenic, or vascular causes may also occur. Blood can originate from the chest wall, intercostal vessels, great vessels, myocardium, lung parenchyma, diaphragm, or the abdomen [6]. Computed Tomography (CT) is the preferred modality to detect fluids in the pleural space. Recent literature suggests point-of-care ultrasound (POCUS) as an adjunct to traditional imaging modalities. However, chest X-Ray remains the most widely used modality [6]. The presence of a bloody effusion with a Hct greater than 50% is diagnostic as mentioned above. The management of hemothorax can range from observation to percutaneous drainage to Video-Assisted Thoracic Surgery (VATS) or open thoracotomy [6].

We report an extremely rare case of massive hemothorax as a result of subclavian central line removal in an Intensive Care Unit (ICU) patient.

## Case Presentation

Our patient is a 72-year-old man known to have hypertension and Alzheimer's disease, who presented to our hospital for decreased level of consciousness and productive cough with respiratory distress. Upon

physical examination, tachypnea, and fever were discovered. He was hemodynamically unstable with borderline blood pressure (100/60 mmHg), tachycardia (heart rate of 122 bpm), and desaturation. His Glasgow Coma Scale (GCS) was below eight, a value that warrants immediate endotracheal intubation. Laboratory investigations at the time of presentation showed elevated WBC (11,400 x 10/L), elevated C-Reactive Protein (CRP) level (118.2 mg/L), elevated troponin level (0.215 ng/ml). Also, no abnormal changes were seen on his electrocardiogram (ECG) thus, the patient was put on dual antiplatelet therapy and prophylactic anticoagulation. Computed Tomography (CT) of the chest showed bilateral lower lobes consolidations and signs of aspiration pneumonia. The patient was then transferred to the ICU, where he was mechanically ventilated on pressure regulated volume control mode, and sedated with midazolam and fentanyl. Intravenous broad-spectrum antibiotic Piperacillin/Tazobactam at a dose of 4.5 grams every 6 hours was initiated. A left subclavian venous catheter was placed anatomically because a peripheral line was hard to establish. The proper placement was confirmed with a Chest X-Ray (figure 1). A few days later, our patient started to have a fever; cultures were taken, including urine culture, deep tracheal aspirate culture, and blood cultures that grew *Candida Kefyr* on chocolate agar medium. Thus, the diagnosis of fungemia was made with the indication of removal of the central venous catheter. In exchange, a peripheral line was established.

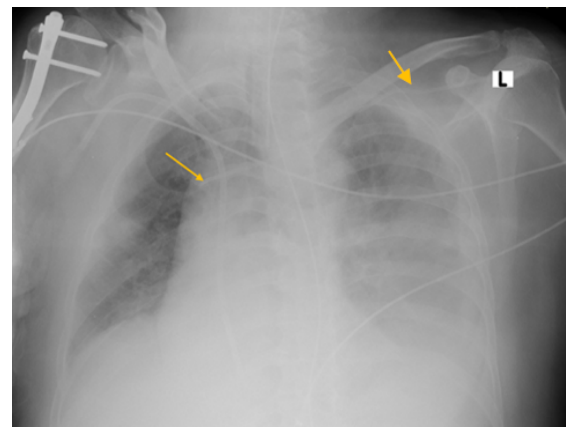
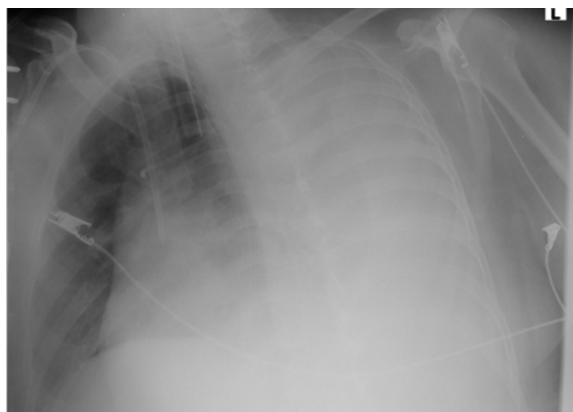

Figure 1: Chest x-ray of the patient showing

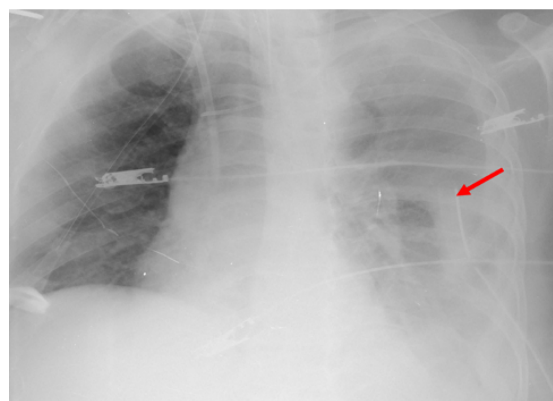*the left subclavian venous catheter in place (yellow arrow) and a small left pleural effusion present since presentation to the hospital probably para-pneumonic.*

Follow-up laboratory findings showed a severe drop in hemoglobin level from 9.2 mg/dl the day the central line was removed to 5.8 mg/dl 24 hours later. Initially, Disseminated Intravascular Coagulation (DIC) was ruled out since no thrombocytopenia and no elevated fibrinogen level. Two blood units were transfused. A chest X-ray performed the day after showed a left white lung (Figure 2). Diagnostic pleural tap drained blood as pleural fluid studies showed: a red blood cell count (RBC) of 2,200,000/microliter with an Hct of 21 % and white blood cell count (WBC) of 4200/microliter, which was similar to the patient CBC with pleural Hct/blood Hct > 90%.



**Figure 2:** Chest x-ray of the patient 24 hours after of the removal of the left subclavian venous catheter removal showing a large pleural effusion.

Tube thoracotomy was done the next day (Figure 3) by the cardiovascular team, draining around 2500 ml of blood in the first 24 hours. Afterward, the amount of blood being drained decreased spontaneously to around 100ml/24 h and remained like that. Unfortunately, our patient developed severe septic shock due to *Acinetobacter Baumannii* multidrug-resistant (MDR) pneumonia that led to his demise.



**Figure 3:** Chest x ray of the patient after left anterior chest tube (red arrow) was placed for drainage of the left hemothorax.

### Discussion

The hospitalized patient often requires the administration of various drugs given through different routes. The venous route is the most widely used when peripheral venous access is difficult to establish. Alternatives are present such as intraosseous lines, external jugular lines, central venous catheters, and peripheral lines placed under ultrasound guidance [7].

In critical patients, the complexity of treatment often requires multiple venous accesses, thus central lines are the modality of choice. The internal jugular vein, subclavian vein, and femoral vein are the common sites for insertion, however, the subclavian vein cannulation has been preferred for its low rate of infections and thrombotic complications but, it is more associated with mechanical complications such as pneumothorax and hemothorax [8,9]. Risk factors leading to subclavian vein catheterization complications include female sex, being under or overweight, previous catheterization, history of surgery or radiation therapy in the region of catheter placement, and more than two needle passages [10].

Whenever venous access is removed, there is a risk of bleeding that can be prevented by applying compression to the site of insertion upon removal and by assessing the patient's coagulation profile. To note, in subclavian access, applying pressure to the vein is difficult, thus, gentle pressure should be

applied as near to the supposed exit site as possible. In our case, the patient had only more than two needle passages. He was on prophylactic anticoagulation and dual antiplatelet therapy for suspicion of non-ST elevation myocardial infarction (NSTEMI), which increases his chance of bleeding after any procedure. Also, few reports elaborate on potential complications related to central line removal. A case was described in 1982 by Nordbank et al. when a massive hemothorax developed after subclavian central line removal in a 13 months child [8]. Another one was described in 2002 by Andrea Collini et al., when a severe hemothorax developed in a 51-year-old female patient, a few minutes after central venous catheter removal [9]. A third one was also reported in Korea, where a hemothorax occurred ten minutes after the removal of the subclavian catheter. The latter reports the reason to be an injury to the superior vena cava, as found after thoracotomy for treatment [3]. However, in our case, the bleeding stopped so no surgical intervention was done to further investigate the reason.

There is still no explanation behind the late hemorrhagic complications of central venous catheterization, but suggestions included procedure-related injuries and erosion of the vessel wall by the catheter itself or by hyperosmolar solutions [3,9,10]. We believe that the difficult insertion of the central venous catheter may have caused vessel erosions, and the altered bleeding diathesis by the antiplatelet is the reason behind our patient's rare occurrence. Therefore, ultrasound-guided central venous cannulation can be very useful, with reductions in the failure rate from 55% to 8% and the complication rate from 41% to 4% were reported when compared to anatomic landmark-based techniques [3]. Hence, we suggest that proper insertion techniques be applied, and training to use ultrasound-guided techniques can prevent the occurrence of such fatal complications.

The limitation of our report is that no surgical intervention or autopsy was performed to elucidate the pathophysiology of the hemothorax in relation to the removal of the catheter.

## Conclusion

In conclusion, physicians are always aware of the more common complications related to catheters insertion, such as pneumothorax, thrombosis, and infections, but attention to central lines removal is also warranted because such complications although very rare, can happen. Thus, we emphasize monitoring of patients after catheter removal because the uncommon nature of this complication can lead to diagnosis delay and even misdiagnosis.

## References

1. Santos FKY, Flumignan RLG, Areias LL, et al. Peripherally inserted central catheter versus central venous catheter for intravenous access: A protocol for systematic review and meta-analysis. *Medicine (Baltimore)*. 2020;99(30):e20352. PMID: 32791657. <https://doi.org/10.1097/MD.00000000000020352>
2. Velasquez Reyes DC, Bloomer M, Morphet J. Prevention of central venous line associated bloodstream infections in adult intensive care units: A systematic review. *Intensive Crit Care Nurs*. 2017;43:12-22. PMID: 28663107. <https://doi.org/10.1016/j.iccn.2017.05.006>
3. Lee HK, Hong SW, Kim GJ, Ryu T, Han JK, Kim JC. Massive hemothorax immediately after removal of central venous catheter -A case report-. *Korean J Anesthesiol*. 2013;65(1):77-79. PMID: 23904944. <https://doi.org/10.4097/kjae.2013.65.1.77>
4. Merrer J, De Jonghe B, Golliot F, et al. Complications of femoral and subclavian venous catheterization in critically ill patients: a randomized controlled trial. *JAMA*. 2001;286(6):700-707. PMID: 11495620 <https://doi.org/10.1001/jama.286.6.700>
5. Drewett SR. Central venous catheter removal: procedures and rationale. *Br J Nurs*. 2000;9(22):2304-2315. PMID: 12271197. <https://doi.org/10.12968/bjon.2000.9.22.5417>
6. Zeiler J, Idell S, Norwood S, Cook A. Hemothorax: A Review of the Literature. *Clin Pulm Med*. 2020;27(1):1-12. PMID: 33437141. <https://doi.org/10.1097/CPM.0000000000000043>
7. American College of Emergency Physicians. Alternative methods to vascular

access in the emergency department. Policy statement. *Ann Emerg Med.* 2011;58(4):402. PMID: 21943586. <https://doi.org/10.1016/j.annemergmed.2011.07.015>

8. Nordback I, Baer G. Massive hemothorax in a child after removal of subclavian vein catheter. *Acta Chir Scand.* 1982;148(8):701-702. PMID: 7170906.

9. Collini A, Nepi S, Ruggieri G, Carmellini M. Massive hemothorax after removal of subclavian vein catheter: a very unusual complication. *Crit Care Med.* 2002;30(3):697-698. PMID: 11990937. <https://doi.org/10.1097/00003246-200203000-00034>

10. Duntley P, Siever J, Korwes ML, Harpel K, Heffner JE. Vascular erosion by central venous catheters. Clinical features and outcome. *Chest.* 1992;101(6):1633-1638. PMID: 1600785. <https://doi.org/10.1378/chest.101.6.1633>