



Vitamin D Deficiency Mimicking Pseudohypoparathyroidism Type II in an Adolescent Boy: A Case Report

Andrew Shieh, MD^{1,2}, Griselda Alvarez, MD³

¹Irvine Medical Center, University of California, Irvine, California, USA

²University of Michigan Hospital, Ann Arbor, Michigan, USA

³Miller Children's & Women's Hospital Long Beach, Long Beach, California, USA

Corresponding Author: Griselda Alvarez, Long Beach, CA, galvarez@memorialcare.org

doi: <https://doi.org/10.38179/ijcr.v3i1.126>

Abstract

Background: Vitamin D deficiency in children is common and usually characterized by hypocalcemia, hypophosphatemia, and elevated serum parathyroid hormone level. However, vitamin D deficiency can be associated with parathyroid hormone resistance in the kidneys which may cause hyperphosphatemia instead, mimicking thus pseudohypoparathyroidism type II. The exact pathogenesis for parathyroid hormone resistance remains unclear, and the distinction between the two conditions remains difficult. We describe the case of an adolescent who presented with seizures and was found to have biochemical features consistent with pseudohypoparathyroidism, likely related to vitamin D deficiency.

Case Report: A 13-year-old previously healthy adolescent presented with seizures. He experienced back pain during the previous month prior to the presentation. He did not have features of Albright hereditary osteodystrophy. His laboratory studies were significant for hypocalcemia, hyperphosphatemia, elevated serum alkaline phosphatase level, elevated parathyroid hormone level, and a deficient vitamin D level. Magnetic resonance imaging of the spine revealed multiple compression fractures. The child was treated with intravenous calcium and vitamin D administration with rapid improvement and his seizures resolved.

Conclusion: Hypocalcemia from vitamin D deficiency can mimic pseudohypoparathyroidism type II. The principles of treatment for hypocalcemia in both conditions are similar and patients require timely intervention with close follow-up to ensure the resolution of symptoms. Patients with resolution of symptoms after adequate treatment may not require further evaluation for other types of pseudohypoparathyroidism.

Keywords: Hypocalcemia, Pseudohypoparathyroidism, Vitamin D deficiency, Seizure, Endocrinology

Received: 2021.07.20
Accepted: 2022.10.25
Published: 2022.06.16

Financial support: None
Conflict of interest: None
Patient Consent: Written consent was obtained from the patient and his parents for the publication of this case and accompanying images.

Introduction

Parathyroid hormone (PTH) is produced by the parathyroid glands and consists of 84 amino acids synthesized into a single-chain polypeptide [1]. Its two principal target tissues are the kidneys and bones. In bone, PTH acts on osteoblasts to promote mineralization when PTH is within physiological concentrations [1]. When the level of PTH rises during hypocalcemia, the hormone stimulates osteoclasts to promote bone resorption and increase serum calcium [1,2]. PTH stimulates the action of the enzyme 1- α -hydroxylase within the proximal convoluted tubule of the nephron to convert circulating 25(OH)D₃ to its active metabolite, 1,25(OH)₂D₃ [1,3]. PTH also promotes the reabsorption of magnesium and calcium in the distal nephron while enhancing renal phosphate excretion [1]. Parathyroid hormone resistance disorders refer to a group of heterozygous conditions characterized by hypocalcemia which occurs due to defects towards the end of the calcium cascade [2,4,5]. It is usually, but not always, accompanied by an elevated PTH level and hyperphosphatemia [2,4]. The two most notable conditions that can cause PTH resistance are deficiencies in the supply or metabolism of vitamin D and pseudohypoparathyroidism [4,5].

Vitamin D deficiency is common in children, especially among Hispanic and African American adolescents [3,4]. The most common etiologies of vitamin D deficiency include limited sunlight exposure, poor nutritional intake, and obesity [3]. Medications such as antiepileptic drugs and systemic glucocorticoids have been shown to reduce serum 25(OH)D₃ concentrations when sunlight exposure and dietary intake are limited. Chronic conditions such as cystic fibrosis, celiac disease, and inflammatory bowel diseases are known to interfere with vitamin D absorption and metabolism in the intestine [3]. Deficiency in vitamin D leads to a reduction in intestinal calcium absorption which causes hyperparathyroidism [3,4].

Pseudohypoparathyroidism (PHP) is a rare

disorder caused by resistance or unresponsiveness to PTH in the kidneys, bones, and intestine [2,4,5]. It was first highlighted by Fuller Albright in 1942 as a mechanism of disease when several patients who had biochemical features of hypoparathyroidism failed to respond to injection of parathyroid hormone extract and remained with hypocalcemia and hyperphosphatemia [2]. The prevalence of PHP is low and there is often no family history of the condition. Previous studies have estimated the condition to occur below 1 case per 100,000 population depending on the geographic location [5]. The average age at diagnosis is thirteen years old, with females at higher risk than males [4]. PHP is distinguished into two different types, and type 1 is further delineated into three categories [2,4,5]. Here, we report the case of a 13-year-old boy with a first-time seizure who was found to have severe hypocalcemia due to vitamin D deficiency mimicking pseudohypoparathyroidism.

Case Presentation

We describe a 13-year-old Caucasian boy who presented to the hospital with a generalized tonic-clonic seizure for ten minutes. The patient had been complaining of mild pain in his neck and back beginning one month prior to presentation. The patient had no prior history of seizures. He was fully immunized and had no known allergies. There was no history of seizures in the family.

On initial physical examination, the patient was sleeping without distress. He was afebrile with tachycardia of 114 beats/min, normal respiratory rate of 16 breaths/min, normal blood pressure of 117/70 mmHg, and 99% oxygen saturation on room air. He was oriented to person and place, but not time. He answered questions slowly. He had difficulty cooperating with commands due to impaired awareness. He had no cranial nerve deficits and was able to move his extremities. His pupils were round and equal, reactive to light bilaterally. His muscle tone was normal. His reflexes were normal bilaterally.

His initial screening laboratory tests were

significant for a calcium of 4.9 mg/dL (8.5-10.1 mg/dL), phosphorus 6.5 mg/dL (2.4-5.1 mg/dL), and alkaline phosphatase activity of 662 U/L (0-299 U/L) (Table 1). His ionized calcium level was 0.67 mmol/L (1.12-1.32 mmol/L) and his parathyroid hormone level was 752 pg/mL (18.5-88.0 pg/mL). His serum magnesium level was within normal limits. Thyroid function tests were within normal limits. Electrocardiography revealed a normal sinus rate with a prolonged QTc interval of 530 milliseconds. No acute ST-segment changes were noted. A non-contrast-enhanced computed tomographic scan of the head showed no acute infarct, mass, or hemorrhage.

After initial stabilization with intravenous fluids, his serum 25(OH)D3 level was found to be 6 ng/mL (20-100 ng/mL) and his 1,25(OH)2D3 level was 48 pg/mL (20-79 pg/mL) (Table 1). A metabolic skeletal radiograph revealed mildly osteopenic bones without dysplasia or evidence of rickets. Non-contrast enhanced magnetic resonance imaging of the spine revealed subtle ill-defined hyperintense signal abnormalities suggestive of multiple compression fractures in the cervical and thoracic spine (Figure 1). The patient was admitted to the pediatric intensive care unit and treated with multiple doses of intravenous calcium gluconate initially. He was transitioned to oral calcium carbonate to provide elemental calcium 80 mg/kg/day and oral high-dose calcitriol daily after serum calcium was above 7 mg/dL. In addition, he received oral cholecalciferol 4,000 units daily and oral ergocalciferol 50,000 units weekly without complications. His prolonged QTc interval resolved. A single-nucleotide polymorphism microarray did not identify clinically significant copy number variants. Exome sequencing of 15 genes associated with hypoparathyroidism (AIRE, AP2S1, CASR, FAM111A, GATA3, GCM2, GNA11, GNAS, HADHA, HADHB, PTH, PTH1R, SOX3, STX16, TBCE) revealed no pathologic variants. Response to exogenous PTH administration by measurement of

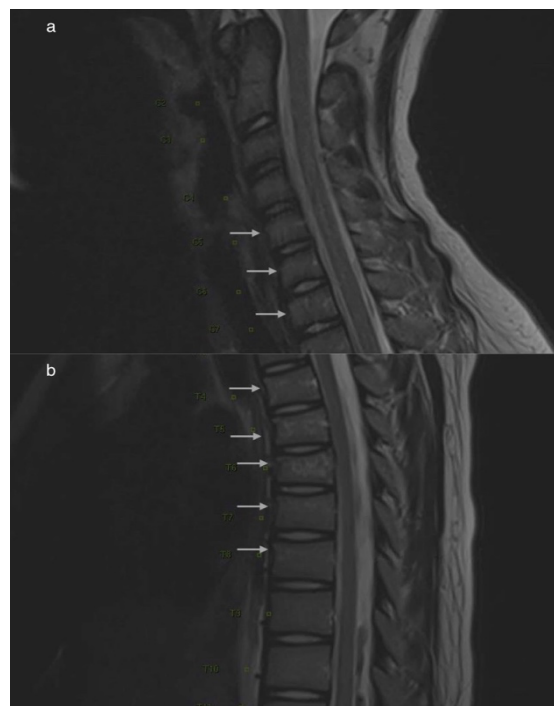


Figure 1: Sagittal T1-weighted magnetic resonance imaging of cervical and thoracic spine revealing multiple compression fractures involving C5-T1 vertebral bodies (a) and T4-T8 (b).

urinary cyclic adenosine monophosphate (cAMP) could not be obtained due to a lack of available testing. He was educated on calcium-rich foods throughout his hospitalization.

The patient was discharged after serum calcium was stable above 8 mg/dL. He was placed in a brace to treat his compression fractures. In follow-up, he finished six doses of oral ergocalciferol with the improvement of his serum 25(OH)D3 level and continued with maintenance of cholecalciferol and calcitriol. His serum parathyroid hormone had decreased to 69 pg/mL after three months (Table 1). His calcium carbonate dose was sequentially lowered, and he remained free of seizures. His vitamin D deficiency resolved after six months, and his hyperphosphatemia resolved after twelve months (Table 1). Persistence of hyperphosphatemia despite resolution of vitamin D deficiency points to a diagnosis of PHP type II and requires further workup to exclude other types of PHP.

Table 1: Major laboratory results during treatment overtime

Laboratory study	Initial presentation	1 week later	3 months later	6 months later	12 months later	18 months later
Calcium (mg/dL)	4.9	9.0	10.1	10.0	9.8	9.9
Phosphorus (mg/dL)	6.5	6.4	7.0	5.4	4.8	3.9
25(OH)D3 (ng/mL)	6	Not obtained	28	43	45	39
PTH (pg/mL)	752	Not obtained	69	49	21	20

Discussion

One percent of children will have an afebrile generalized seizure by age seventeen years [6]. Seizures in adolescents may be caused by hypoxia, ischemia, infection, toxin, or medications. Structural abnormalities include trauma, tumor, malformation, or hemorrhage. Acute management focuses on maintaining control of the airway, breathing, circulation, and when appropriate, cessation of seizures with benzodiazepines. Diagnostic workup for new-onset seizure may include laboratory studies to assess electrolyte disturbances, imaging of the head with computed tomographic scan/magnetic resonance imaging, electroencephalogram, and lumbar puncture. Symptoms of severe hypocalcemia include seizures, tetany, apnea, and muscle twitching or spasms [3,4]. Biochemical evaluation of symptomatic hypocalcemia should include serum calcium, phosphate, parathyroid hormone level, 25(OH)D3 level, and alkaline phosphatase activity [1,2,3]. Often, urine calcium and phosphate, as well as serum 1,25(OH)2D3 level are also obtained [4]. Vitamin D status is defined by serum 25(OH)D3 according to the Endocrine Society [3]. If the level is lower than 20 ng/mL, a patient has vitamin D deficiency [4]. If the level is between 21-29 ng/mL, a patient has vitamin D insufficiency. A patient has vitamin D sufficiency if the level is above 30 ng/mL [3,4]. If a patient has hypocalcemia, hyperphosphatemia, and elevated parathyroid hormone level, PHP must be considered especially if the patient's

electrolyte abnormalities do not resolve after initial management (Table 2) [2,4,5]. Type IA, which is the most common subtype, is due to a mutation in the GNAS1 gene [2,5,7]. The GNAS1 gene encodes a subunit of guanine nucleotide-binding protein, which triggers a network of signaling pathways that ultimately regulate the activity of other hormones [2]. Patients present with physical findings consistent with Albright hereditary osteodystrophy (AHO): short stature, stocky habitus, moon-shaped face, intellectual disability, hypoplasia of enamel in teeth, and anomalies of hands and feet [2,5]. Patients with Type IB often have a normal GNAS1 gene but with epigenetic defects [2,5]. They do not have an AHO phenotype but frequently have osteitis fibrosa cystica. Patients with PHP type IC present with a phenotype consistent with AHO and resistance to other hormones including thyroid-stimulating hormone, growth hormone-releasing hormone, and gonadotropins [2]. Urinary cAMP response to exogenous PTH is diminished in all subtypes of PHP type I. Patients with type II have no GNAS1 defect, no AHO phenotype, and have target tissue resistance only to parathyroid hormone [2,5]. Nephrogenic cAMP response to exogenous PTH administration is normal. Vitamin D deficiency, which usually presents with low serum Ca²⁺, low to normal serum phosphorus, and elevated alkaline phosphatase activity, must be considered as well because vitamin D deficiency has been reported to present with hyperphosphatemia and has been reported

Table 2: Classifying different types of pseudohypoparathyroidism

PHP Type	Mechanism	AHO phenotype	Urinary cAMP response to PTH	Other hormone resistance
IA	GNAS1 mutation (maternal)	Yes	↓	Yes
Pseudo-PHP	GNAS1 mutation (paternal)	Yes	Normal	No
IB	Defect in regulation of PTH receptor	No	↓	No
IC	GNAS1 normal	Yes	↓	Yes
II	Acquired defect, unknown	No	Normal	No

to mimic PHP type II similar to our patient [5,8]. Distinguishing among the different types of pseudohypoparathyroidism is important to help patients understand their condition, provide anticipatory guidance for expected symptoms, and promote compliance with medications.

Intravenous calcium is the recommended intervention in patients with acute hypocalcemia regardless of the etiology [9]. Calcium gluconate must be administered slowly to avoid cardiac conduction irregularities and can be repeated every six hours. If normocalcemia is not achieved, patients may require a continuous calcium (20-80 mg Ca²⁺/kg/24h) infusion until normal levels are achieved [9]. Hypomagnesemia should be treated with MgSO₄ (50% solution) 25-50 mg Mg²⁺/kg intravenously every four hours. When normomagnesemia is achieved, patients may require oral treatment with 30-60 mg Mg²⁺/kg daily.

Once the patient is no longer symptomatic, intravenous therapy should be transitioned to oral therapy. Many types of supplements are available; calcium carbonate contains 40% elemental Ca, calcium citrate contains 21%, and calcium gluconate contains 9.4% [9,10]. The dose should provide at least 25 and up to 100 mg elemental Ca²⁺/kg/day divided at least every six hours. Higher doses of calcium supplements may be

to overcome chronic hypocalcemia. In patients for whom there is difficulty in achieving normocalcemia, thiazide diuretics may be used to limit hypercalciuria as calcium supplements are titrated. Urine calcium/urine creatinine should be monitored to avoid the accumulation of calcium salts in the kidneys. The patient can be discharged from the hospital with a lower dose of calcium supplement once normocalcemia occurs.

Vitamin D therapy is required to treat parathyroid hormone resistance disorders and vitamin D deficiency and should be started immediately [3]. Cholecalciferol 2,000 to 4,000 international units per day or weekly intramuscular injections of 50,000 units for six weeks followed by 1,000 units per day orally should be used to achieve and maintain 25(OH)D₃ at a sufficient level [3,9]. If an intramuscular injection is not desirable, cholecalciferol should be substituted with ergocalciferol 50,000 units weekly for six weeks [10]. Calcitriol should also be started with a dose of up to 50 ng/kg daily to increase calcium absorption and its dosage should be adjusted while monitoring serum calcium and phosphorus levels [9]. It is especially important in patients with hypocalcemia from liver disease, renal failure, or defects in 1- α -hydroxylase function. Calcitriol in high doses along with chronic parenteral calcium is effective in patients with 1- α -hydroxylase deficiency or vitamin D dependent rickets [11].

Regardless of etiology, patients with severe hypocalcemia require frequent follow-up to ensure adequate calcium levels and rule out the presence of nephrocalcinosis and hematuria.

Conclusion

Pseudohypoparathyroidism is characterized by tissue resistance to parathyroid hormone in the kidneys, bones, and intestine. Pseudohypoparathyroidism type IA and IC are associated with a constellation of findings known as Albright hereditary osteodystrophy, while type IB and II do not have the associated phenotype. Patients with severe vitamin D deficiency show hypocalcemia and high parathyroid hormone level. If accompanied by hyperphosphatemia, vitamin D deficiency may present biochemically as pseudohypoparathyroidism type II. Regardless of the etiology, treatment of hypocalcemia as a result of pseudohypoparathyroidism type II and vitamin D deficiency are similar. Patients may require further investigation for other types of pseudohypoparathyroidism if electrolyte abnormalities persist despite adequate treatment.

References

1. Murray TM, Rao LG, Divieti P, et al. Parathyroid Hormone Secretion and Action: Evidence for Discrete Receptors for the Carboxyl-Terminal Region and Related Biological Actions of Carboxyl-Terminal Ligands. *Endocrine Reviews*. 2005;26(1):78-113. PMID: 15689574. <https://doi.org/10.1210/er.2003-0024>.
2. Turan, S. Current Nomenclature of Pseudohypoparathyroidism: Inactivating Parathyroid Hormone/Parathyroid Hormone-Related Protein Signaling Disorder. *Journal of Clinical Research in Pediatric Endocrinology*. 2017;9(Suppl 2):58-68. PMID: 29280743. <http://doi.org/10.4274/jcrpe.2017.S006>.
3. Holick MF, Binkley NC, Bischoff-Ferrari HA, et al. Evaluation, treatment, and prevention of vitamin D deficiency: an Endocrine society clinical practice guideline. *Journal of Clinical Endocrinology and Metabolism*. 2011;96(7):1911-1930. PMID: 21646368. <http://doi.org/10.1210/jc.2011-0385>.
4. Underbjerg L, Sikjaer T, Mosekilde L, et al. Pseudohypoparathyroidism- epidemiology, mortality and risk of complications. *Clinical Endocrinology*. 2016;84(6):904-911. PMID: 26387561. <http://doi.org/10.1111/cen.12948>.
5. Mantovani G, Bastepe M, Monk D, et al. Diagnosis and management of pseudohypoparathyroidism and related disorders: first international Consensus Statement. *Nature Reviews Endocrinology*. 2018;14:476-500. PMID: 29959430. <http://doi.org/10.1038/s41574-018-0042-0>.
6. Cui W, Kobau R, Zack MM, et al. Seizures in Children and Adolescents Aged 6-17 Years-United States, 2010-2014. *Morbidity and Mortality Weekly Report- CDC*. 2015;64(43):1209-1214. PMID: 26540283. <http://doi.org/10.15585/mmwr.mm6443a2>.
7. Burgert T, Markowitz M. Understanding and Recognizing Pseudohypoparathyroidism. *Pediatrics in Review*. 2005(8);26:308-309. <https://doi.org/10.1542/pir.26-8-308>
8. Felner EI, Marks JF, Germak JA. A variation of vitamin D deficiency in children. *Journal of Pediatric Endocrinology and Metabolism*. 2001;14(2):203-206. PMID: 11305799. <http://doi.org/10.1515/jpem.2001.14.2.203>.
9. Brook CG, Brown RS. *Handbook of Clinical Pediatric Endocrinology* First Edition. Malden, MA: Blackwell Publishing, Inc; 2008.
10. Misra M, Pacaud D, Petryk A, et al. Vitamin D Deficiency in Children and its Management: Review of Current Knowledge and Recommendations. *Pediatrics*. 2008;122(2):398-417. PMID: 18676559. <http://doi.org/10.1542/peds.2007-1894>.
11. Edouard T, Alos N, Chabot G, et al. Short- and long-term outcome of patients with pseudo-vitamin D deficiency rickets treated with calcitriol. *Journal of Clinical Endocrinology and Metabolism*. 2011;96(1):82-89. PMID: 20926527. <http://doi.org/10.1210/jc.2010-1340>.