

The Simultaneous Occurrence of Acute Appendicitis and Bowel Perforation in *Taenia* Infection: A Case Report

Mohammad Rida Farhat, MD¹, Firas Francis Ibrahim, MD¹, Kassem Mohammad Jamoul, MD¹, Rama Z. Bdeir, MD¹, Zahraa H. Moussawi, MD¹, Khaled Rida, MD²

¹Department of General Surgery, Lebanese University, Faculty of Medical Sciences, Beirut, Lebanon

²Department of General Surgery, Bahman University Hospital, Beirut, Lebanon

Corresponding Author: Mohammad Rida Farhat, Department of General Surgery, Bahman University Hospital, Beirut, Lebanon, farhat.mhd@outlook.com

doi: <https://doi.org/10.38179/ijcr.v3i1.154>

Abstract

Background: Appendicitis is most likely due to obstruction of the appendiceal lumen. Parasitosis is an unusual cause of obstruction and in specific, *Taenia Saginata* is a very rare cause of appendicitis, even more so of small bowel perforation. Teniosis is usually an asymptomatic process but a greater load or migration of the adult form may complicate some cases. The simultaneous occurrence of acute appendicitis and ileal perforation in the same setting has not been reported in the literature.

Case Presentation: A 60-year-old Lebanese female patient presented to the emergency department with right lower quadrant pain radiating to the left lower abdomen. The patient reported associated fever, chills, and anorexia prior to presentation. On physical examination, she was afebrile and normotensive, abdominal examination revealed diffuse lower abdominal tenderness. A blood workup revealed an elevated C-reactive protein (CRP) value with a normal white blood count (WBC). Computed tomography (CT) scan done with intravenous (IV) and per os (PO) contrast disclosed a leak of PO contrast in the absence of pneumoperitoneum implying a contained perforated appendicitis or colitis. The patient underwent urgent laparoscopic exploration. Intraoperatively patient had gangrenous appendicitis and an inflamed right fallopian tube, as well as small bowel perforation and the presence of a tapeworm. The tapeworm was removed and the patient ended up having an appendectomy, right salpingectomy, and oophorectomy, with the closure of ileal perforation. Her hospital stay was uneventful and she was discharged on ciprofloxacin, mebendazole, and metronidazole. Soon after her discharge from the hospital, the patient resumed her normal daily activities. Histopathological studies revealed mixed inflammatory infiltrates and the worm to be *Taenia Saginata*.

Conclusion: Patients with teniosis are mostly asymptomatic. In symptomatic patients, the course is usually mild except for some rare occasions including appendicitis or bowel perforation. The diagnosis of *Taenia Saginata* infection in such cases should be considered in endemic areas such as the Middle East and North Africa (MENA) region where eating raw meat is habitual.

Keywords: Appendicitis, Ileal perforation, Abdominal pain, *Taenia Saginata*, Intestinal obstruction, Surgical emergency

Received: 2022.12.29
Accepted: 2022.02.13
Published: 2022.08.01

Financial support: None
Conflict of interest: None
Ethical approval: Written consent was obtained from the patient for the publication of this case and accompanying images.

Background

Appendicitis is the most common abdominal surgical emergency in children and young adults [1]. Its cause is still not clear but theories suggest it's due to obstruction of the appendiceal lumen which increases intraluminal pressure, leading to vascular compromise then bacterial invasion, inflammation, and finally tissue necrosis [1]. This obstruction may result from infections and follicular lymphoid hyperplasia in the young, while fibrosis, fecaliths, and sometimes neoplasms are the major causes in older populations [2]. Rarely, it is due to parasitosis [2]. The diagnosis of acute appendicitis is often achieved clinically where it typically presents with abdominal pain, decreased PO intake, nausea, and vomiting [3]. Physical examination may reveal positive Rovsing sign, obturator sign, psoas sign, and absence of bowel sounds [3]. Generally, imaging studies can help confirm the suspicion of acute appendicitis; especially CT scans which are more sensitive and specific than ultrasonography [3]. As for management, it is typically surgical appendectomy, more commonly laparoscopic than open [3].

The association of parasitic infections -with acute appendicitis remains controversial and has been under investigation for quite some time now. *Enterobius vermicularis* happens to be the culprit in most of the cases, and less frequently we find *Ascaris*, *Giardia*, *Entamoeba histolytica*, and *Taenia* [2,4,5]. *Taenia saginata* is a zoonotic parasite commonly known as beef tapeworm [6]. It is acquired by bovines through ingestion of water or food contaminated by stools of human carriers containing eggs or proglottids [6]. Humans become infected after consumption of cyst-infected bovine meat [6].

The intestinal infestation with the adult form of the parasite, termed Teniosis, is usually an asymptomatic process [7]. Sometimes, it may induce mild vague abdominal pain with minor complications over several years [7]. Less commonly, patients may experience nausea, vomiting, weight loss, and intestinal obstruction [8]. The active passage of proglottid segments in feces is the most prevalent sign of infection [9]. In rare cases, when the tapeworm migrates to occlude canals and lumens, it can cause cholecystitis,

pancreatitis, Meckel's diverticulitis, and acute appendicitis [8]. There have been few reports of *Taenia Saginata* infection associated with either appendicitis or intestinal perforation [9-12]. However, small bowel perforation due to *Taenia Saginata* occurring simultaneously with acute appendicitis is uncommon with no such reported cases in the literature.

We hereby report a case of acute gangrenous appendicitis associated with ileal perforation found to be caused by *Taenia Saginata*.

Case Presentation

A 60-year-old Lebanese woman, with a past medical history relevant for Familial Mediterranean Fever (FMF) on colchicine, and Rheumatoid Arthritis (RA) treated by nonsteroidal anti-inflammatory drugs (NSAIDs), presented to the emergency department with right lower quadrant pain. She has no known food or drug allergies and has only undergone hysterectomy years ago. Two days before her presentation, the patient had been experiencing stabbing pain in her right lower quadrant which progressed in severity and started radiating to her left lower abdomen. The pain was refractory to usual pain killers and antispasmodics but associated with chills, a documented fever of 40° celsius once, and anorexia one day prior to her presentation. The patient did not recall nausea, vomiting, or any change in her regular bowel habits. On physical examination, the patient was afebrile and normotensive. Abdominal examination revealed diffuse lower abdominal tenderness with positive McBurney, Rovsing, and obturator signs. Blood tests were unremarkable except for a highly elevated CRP of 281 mg/L. CT scan of abdomen and pelvis done with injected IV and PO contrast revealed diffuse mesenteric infiltration of the right-sided pelvis, with normal terminal ileum, and leakage of oral contrast media at the lower aspect of the caecum communicating with a 45mm well-defined inflammatory collection compatible with perforated appendicitis or colitis (figure 1). However, there was no evidence of pneumoperitoneum, suggesting a contained perforation. The patient was admitted, IV hydration and broad-spectrum antibiotics were started. Informed consent was then obtained to proceed with urgent laparoscopic exploration and appendectomy.

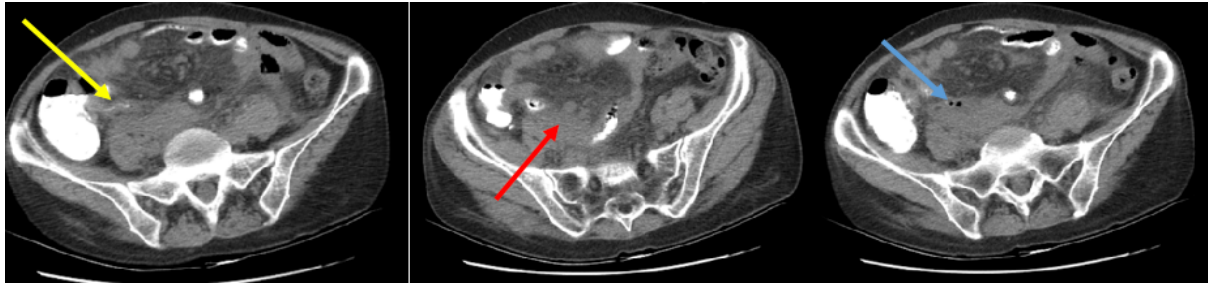


Figure 1: Abdominal CT scan (axial view) prior to surgery showing inflamed appendix (yellow arrow), phlegmon in the right iliac fossa (red arrow), and free air inside the phlegmon (blue arrow) caused by perforation. No signs of pneumoperitoneum.

After insufflation of the abdomen, laparoscopic exploration demonstrated extensive adhesions, pseudomembranes, and a phlegmon formation at the right iliac fossa. Meticulous, blunt, sharp, and hydro-dissection were performed to liberate the small bowels from the caecum and the right adnexa. A gangrenous appendicitis was identified with a healthy base and severely inflamed right fallopian tube (figure 2).

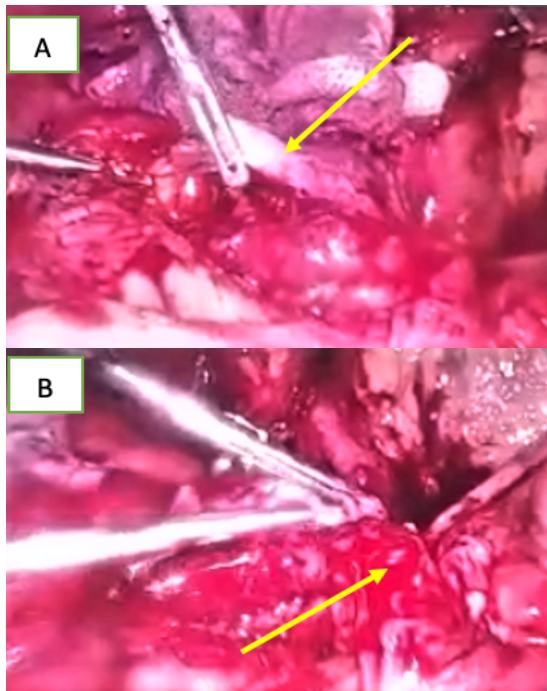


Figure 2: Severe inflammation of the right fallopian tube (A) along with gangrenous appendicitis (B).

During dissection of appendectomy, a small bowel perforation was recognized at about 30 cm from the ileocaecal valve (figure 3). A 75cm tapeworm fragment was extracted through this 1 x 1cm perforation which was then closed by interrupted sutures (figure 3).

Appendectomy was completed by dissection of the mesoappendix, ligation of the appendicular base, and finally separation.

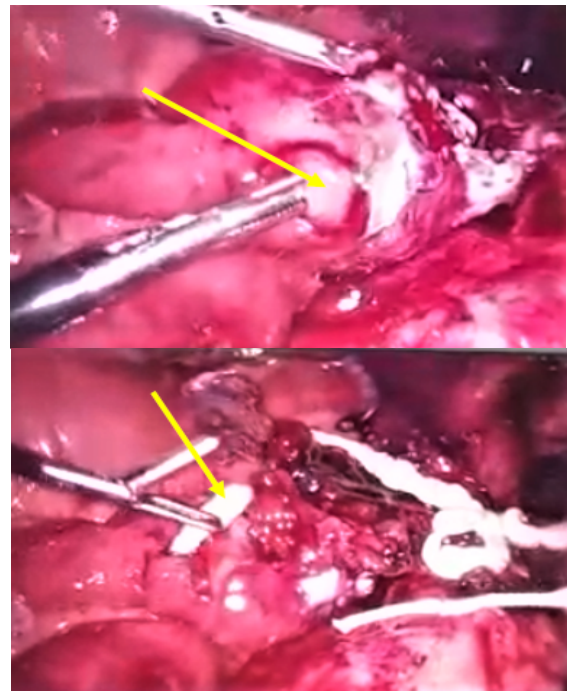


Figure 3. Intraabdominal laparoscopy showing small bowel perforation with an underlying taenia saginata.

Based on the gynecological team consultation, resection of the right fallopian tube was done along with a right oophorectomy for severe inflammation. Appendix, right adnexa, and the tapeworm were sent for histopathological study. Before exsufflation and wound closure, irrigation and suction were done and a drain was placed at the right iliac fossa.

The patient was extubated and then observed in the recovery before she was transferred to the regular floor in a good condition. On the first postoperative day, the patient was doing well on hydration, antibiotics, and pain killers.

The postoperative stay was uneventful. On the sixth postoperative day, the patient was stable, tolerating full fluids. The patient was discharged home on ciprofloxacin, metronidazole, and mebendazole 300mg PO twice daily for three consecutive days. After one week, the patient was followed up at the clinic, the sutures were removed and she regained her normal activity.

Histopathologic study of the specimens showed severe mixed inflammatory infiltrate into the appendicular wall and peri-appendicular fat, mixed inflammatory infiltrates in the right adnexa, and intestinal tapeworm: *Taenia Saginata*.

Discussion

Taenia saginata commonly known as beef tapeworm is a type of zoonotic parasite [13]. Its prevalence is highest in the MENA region and reportedly affects from 0.02 to 8.6% of the population [13]. This can be attributed to the generally low economical status which limits access to the already frail healthcare system [13]. Add to that the cultural habits in that region which include raising cattle and consuming raw and undercooked meat regularly, and this is the main mode of transmission of *Taenia Saginata* [13]. Its life cycle involves an intermediate host, the bovines, in which it causes cysticercosis, and a definitive host, the humans, where carriers develop taeniosis. The latter is a term describing the intestinal infestation with the adult form of the parasite. Once in the intestine, an adult worm can produce several thousand eggs which can be excreted in stool either freely or within proglottids. Bovines then become infected by consuming eggs that develop into the oncosphere which reach muscles through blood and turn into cysticerci, the larval form. The cycle is complete when humans ingest infected undercooked or raw meat making them prone to infestation by *Taenia Saginata* [6,8,13]. In our case, the patient recalled consuming plates from the Lebanese cuisine with raw meat as the main ingredient. She also denied consuming pork meat due to religious beliefs.

Teniosis is usually an asymptomatic process. However, when symptoms do occur, they range from mild abdominal discomfort to more severe and rare manifestations including

intestinal obstruction and sometimes even perforation [7,8]. Small bowel perforation due to *Taenia Saginata* is so rare that it was reported only a few times in literature [10-12,14]. Usually, small bowel perforations caused by *Taenia* occur secondary to obstruction and pre-obstructive build-up of pressure which increases contact between the parasite and intestinal mucosa. This results in inflammation and edema, and subsequently perforation [12].

In our case, the patient presented with atypical signs and symptoms of acute appendicitis. However, intraoperatively, the patient was found to have, in addition to acute gangrenous appendicitis, an ileal perforation induced by *Taenia Saginata*. Two theories explain these findings. Either the perforation occurred first and triggered the inflammation of the appendix and adnexa, or appendiceal inflammation got complicated thus causing a form of obstruction or pressure build-up amounting to ileal perforation. But taking into consideration the degree of inflammation can hint that appendicitis happened first as it was gangrenous while the perforation was with more or less fresh edges (Figure 2B, 3).

Methods for diagnosing *Taenia* infection have improved. We still rely on the observation of eggs and proglottids in feces under light microscopy. This method has a low sensitivity due to the on/off shedding of eggs but high specificity for *Taenia* species. However, the eggs of different *Taenia* species look similar and cannot be distinguished with microscopy. So, more reliable techniques have been designed and include immunological (ELISA: Enzyme-linked immunosorbent assay) and molecular (PCR: Polymerase chain reaction) testing of feces or serum, and pathologic examination of tissues [15,16].

Following diagnosis, anthelmintic drugs are prescribed including albendazole, niclosamide, and praziquantel with different curative potentials. For prevention, and depending on the prevalence of the parasite, we can proceed with mass drug administration, targeted chemotherapy, and selective chemotherapy. Granted that the cycle requires both bovine and human hosts, we can break it by taking several measures including meat inspection, thorough cooking, limiting contact between cattle and humans,

and following strict hygiene and sanitization protocols. On a broader scale, countries impose regulations and legislations to guarantee that the meat to be consumed is not infected. Note that vaccination against parasites has not been fortunate despite the efforts and money spent [8,16].

Conclusion

Beef tapeworm is commonly overlooked in most cases with gastrointestinal complaints because it is unusual, especially in western developed communities. However, when it should be taken into consideration in developing countries and the MENA region in which raw meat consumption is a common habit. Teniosis is usually asymptomatic or with mild symptoms, mostly vague abdominal discomfort. It is seldom a severe infection and may be complicated by appendicitis and bowel perforations. So, *Taenia Saginata* infection should be included in the differential diagnosis in these cases particularly in endemic areas.

References:

1. Hirsch TM. Acute appendicitis. JAAPA. 2017;30(6):46-47. <https://doi.org/10.1097/01.JAA.0000516357.34621.aa>
2. Alejandro Villalobos C, Fernández-SanMillán D, López-Tomassetti Fernández E, Hernández Hernández JR. Acute appendicitis due to parasitosis. Apendicitis aguda por parasitosis. Cir Esp (Engl Ed). 2018;96(5):306-308. PMID: 29146070. <https://doi.org/10.1016/j.ciresp.2017.09.007>
3. Snyder MJ, Guthrie M, Cagle S. Acute Appendicitis: Efficient Diagnosis and Management. Am Fam Physician. 2018;98(1):25-33. PMID: 30215950.
4. Altun E, Avci V, Azatcam M. Parasitic infestation in appendicitis. A retrospective analysis of 660 patients and brief literature review. Saudi Med J. 2017;38(3):314-318. PMID: 28251230. <https://doi.org/10.15537/smj.2017.3.18061>
5. Taghipour A, Olfatifar M, Javanmard E, Norouzi M, Mirjalali H, Zali MR. The neglected role of *Enterobius vermicularis* in appendicitis: A systematic review and meta-analysis. PLoS One. 2020;15(4):e0232143. Published 2020 Apr 23. PMID: 32324817. <https://doi.org/10.1371/journal.pone.0232143>
6. Torgerson PR, Abdybekova AM, Minbaeva G, et al. Epidemiology of *Taenia saginata* taeniosis/cysticercosis: a systematic review of the distribution in central and western Asia and the Caucasus. Parasit Vectors. 2019;12(1):175. Published 2019 Apr 18. PMID: 30999942. <https://doi.org/10.1186/s13071-018-3079-y>
7. Eichenberger RM, Thomas LF, Gabriël S, et al. Epidemiology of *Taenia saginata* taeniosis/cysticercosis: a systematic review of the distribution in East, Southeast and South Asia. Parasit Vectors. 2020;13(1):234. Published 2020 May 7. PMID: 32381027. <https://doi.org/10.1186/s13071-020-04095-1>
8. Silva CV, Costa-Cruz JM. A glance at *Taenia saginata* infection, diagnosis, vaccine, biological control and treatment. Infect Disord Drug Targets. 2010;10(5):313-321. PMID: 20701576. <https://doi.org/10.2174/187152610793180894>
9. Sharifdini M, Nematdoost K, Shafiei R, Teimouri A. Acute eosinophilic appendicitis caused by *Taenia saginata*: A case report. Ann Med Surg (Lond). 2021;64:102241. Published 2021 Mar 26.. PMID: 33868681. <https://doi.org/10.1016/j.amsu.2021.102241>
10. Soosaraei M, Alizadeh S, Fakhar M, Banimostafavi ES, Hezarjaribi HZ. Intestinal perforation and peritonitis due to *Taenia saginata*: A case report from Iran. Ann Med Surg (Lond). 2017;24:74-76. Published 2017 Nov 15. PMID: 29276585. <https://doi.org/10.1016/j.amsu.2017.11.021>
11. Kurane D, Kurane D. Ileal Perforation Peritonitis Caused By *T. Saginata*: A Case Report. International Journal of Medical Research and Review. 2013;1(3):138-141. <https://doi.org/10.17511/ijmrr.2013.i03.11>

12. Bekraki A, Hanna K. Peritonitis caused by jejunal perforation with *Taenia saginata*: report of a case. *J Parasit Dis.* 2016;40(1):203-204. PMID: 27065626 .
<https://doi.org/10.1007/s12639-014-0447-1>

13. Saratsis A, Sotiraki S, Braae UC, et al. Epidemiology of *Taenia saginata* taeniosis/cysticercosis: a systematic review of the distribution in the Middle East and North Africa. *Parasit Vectors.* 2019;12(1):113. Published 2019 Mar 15. PMID: 30876439.
<https://doi.org/10.1186/s13071-019-3339-5>

14. Vallverdú Scorza M, Zeoli M, Andreoli G, Valiñas R. Perforación duodenal asociada a infestación por tenia saginata [Duodenal perforation associated with taenia saginata infestation]. *Cir Esp.* 2015;93(7):e63-e64.
<https://doi.org/10.1016/j.ciresp.2013.07.007>

15. Aydin Ö. Incidental parasitic infestations in surgically removed appendices: A retrospective analysis. *Diagn Pathol.* 2007;2(1):16.
<https://doi.org/10.1186/1746-1596-2-16>

16. Okello AL, Thomas LF. Human taeniasis: current insights into prevention and management strategies in endemic countries. *Risk Manag Healthc Policy.* 2017;10:107-116. Published 2017 Jun 1. PMID: 28615981.
<https://doi.org/10.2147/RMHP.S116545>