



Pleural Effusion Associated with Ulcerative Colitis: A Case Report

Rana Al Ashkar¹, Rabab Nassereldine MD², Rachad Harb MD³, Mohamed AlMoussawi¹, Khaled Soukarieh MD⁴

¹Faculty of Medical Sciences, Lebanese University, Hadath, Lebanon

²Pulmonary and Intensive Care Unit, Faculty of Medical Sciences, Lebanese University, Hadath, Lebanon

³Cardiology Department, Faculty of Medical Sciences, Lebanese University, Hadath, Lebanon

⁴Gastroenterology, University of Balamand, Beirut, Lebanon

Corresponding author: Rana Al Ashkar, Hadath, Lebanon, rana.ashkar.01@gmail.com

doi: <https://doi.org/10.38179/ijcr.v3i1.197>

Received: 2022.05.16
Accepted: 2023.04.23
Published: 2024.01.07

Financial support: None
Conflict of interest: None
Ethical approval: Written consent was obtained from the patient's parents for the publication of this case and accompanying images

Abstract

Background: Extraintestinal manifestations associated with IBD may involve the skin, joints, hepatobiliary tract, eye, kidney, and rarely pancreas and respiratory systems; as well as risks for venous thrombosis. They may be present at diagnosis or develop later in the disease course. Pulmonary complications of IBD include airway inflammation, parenchymal lung disease, serositis, thromboembolic disease, and drug-induced lung toxicity.

Case Presentation: We report a case of a 41-year-old lady with ulcerative colitis who presented to the hospital with respiratory symptoms. Physical examination and imagery lead to the diagnosis of acute pleural effusion. Later on, the patient developed gastrointestinal symptoms. Colonoscopy and biopsy showed that she has Ulcerative Colitis. Which is a very rare presentation of EIM of IBD. The patient improved on steroids and mesalamine and pleural effusion resolved.

Conclusion: In conclusion, pulmonary involvement should be considered when pleurisy develops in UC. Early diagnosis and effective treatment are important for these patients.

Keywords: *Ulcerative Colitis, Pleural Effusion, mesalamine, Case Report*

Introduction

Inflammatory bowel disease (IBD) is a term for two conditions (Crohn's disease and Ulcerative Colitis) that are characterized by chronic inflammation of the gastrointestinal (GI) tract. IBD is a multifactorial disease, including hereditary, environmental, and immunological components. The disease can present itself with various symptoms such as abdominal pain, bloody or watery stools, weight loss, and fatigue [1].

Whereas IBD is mainly a gastrointestinal disorder, it can also present extra-intestinal manifestations that affect other body systems. IBD is associated with a variety of conditions outside the gastrointestinal tract, termed extraintestinal manifestations (EIM). The latter occurs commonly in patients with IBD (21%-41%) [2]. Most IBD patients with EIMs have colonic inflammation, although some patients develop EIMs before the onset of any gastrointestinal symptoms [3].

One of the "EIM" is pulmonary involvement: the types of airway involvement in IBD include bronchiectasis, which is the most common, acute and chronic tracheobronchitis, bronchiolitis, subglottic stenosis, and fistula formation [4,5]. The pathogenesis of pulmonary involvement in autoimmune diseases such as IBD is unclear. The structural similarity between the intestine and the bronchus, and their common origin from the primitive foregut can explain the development of inflammatory changes in the bronchus in patients with IBD [6,7]. One other explanation, the lymphocytes sensitized from the gastrointestinal tract may induce inflammation in the mucosal surface of other organs such as the pulmonary system. Other studies demonstrated alveolar lymphocytosis in cases of Crohn's disease [8,9].

Rarely, IBD can cause pleural involvement. This invasion can be classified as pneumothorax, pleural thickening, effusion, or inflammation [10].

The diagnosis of respiratory manifestations of IBD can be challenging. Most of the

symptoms are nonspecific and may misguide toward a different diagnosis. Thus, this condition might get underdiagnosed or nearly missed. The latter is also emphasized by multiple previously published case reports on pulmonary manifestations of IBD. Barrecheguren et al. (2020) presented a case of tracheobronchitis associated with ulcerative colitis that was challenging in the diagnosis and treatment phase [11]. Furthermore, Lin Li et al. (2022) highlighted the diagnostic challenges of an interstitial lung disease induced by Crohn's disease [12]. There are no clear guidelines for the management of such conditions. The mainstay in the treatment remains early diagnosis. It also depends on the disease's manifestation and severity. The treatment of the pulmonary manifestations solely will not lead to promising recovery results. Steroids in general have shown a decrease in the illness extent and severity. Other treatment options might be extended to immunosuppressive medications [13]. To our knowledge, this will be the first case reported in Lebanon of a pleural effusion as a first manifestation of Ulcerative colitis resolved on steroid management.

Case Presentation

We present a case of a 41-year-old arab middle eastern lady, who presented to the hospital in November 2020 with dyspnea and pleuritic left chest pain. She also noted a 2-month history of intermittent watery diarrhea and rarely bloody. The patient is known to have a history of Immune Thrombocytopenic Purpura (ITP), is on a taper of prednisone 5 mg po OD, diagnosed a year ago after a history of skin ecchymosis, and hypothyroidism (Hashimoto autoimmune thyroiditis) on Euthyrox 100 mcg orally once daily for 10 years. She has a family history of hypothyroidism in her mother and no history of IBD. Other than that the patient did not have any complaints (no headache, no cough, no fever, no chills, no abdominal pain, no dysuria, no neurologic symptoms).

Her vital signs showed that she was tachycardic (pulse: 110 beats per minute)

yet afebrile with all other parameters in the normal range. On physical examination, only chest auscultation demonstrated some abnormalities with a decreased left basal air entry, and mild left lower quadrant tenderness. There were no lymphadenopathies detected and no other abnormalities. In addition to the initial labs presented in Table 1, electrolytes, liver function tests, lipase, amylase, and creatinine are at normal levels.

Table 1: Initial laboratory findings. WBC: White Blood Cell, CRP: C-Reactive Protein, LDH: Lactate Dehydrogenase.

Laboratory test	Value	Notes
Hemoglobin	11.6 g/dL	
WBCs	9.6 x10 ⁹ cells/L	Neutrophils=87%
Platelets	174 x 10 ⁹ /L	
CRP	29 mg/dL	
LDH	166 IU/L	
Total Serum protein	56 g/L	
D-Dimer	1.04 mg/L	Slightly elevated

HIV, HBV, HCV serologies, and auto-immune workup (ANA, anti-double-stranded DNA, Rheumatoid factor) were negative. PCR SARS-COV-2: negative. Imaging studies were performed and showed the following: Chest X-ray showed moderate pleural effusion (figure 1.a). CT angiography chest showed moderate left pleural effusion millimetric nodules, and mild left atelectasis, no signs of pulmonary embolism and lymph node enlargement were visible (figure 2). A pleural tap and thoracentesis showed an exudative effusion as per light's criteria (Laboratory results shown in Table 2) with normal glucose levels. Gram staining and culture, acid-fast staining, and tuberculosis culture were negative. Polymerase Chain Reaction (PCR) for Tuberculosis also turned out to be negative. No malignant cells were found in pleural fluid. Chest X-ray performed

after pleural tap showed no improvement (figure 1.b). HBs ag and anti-HCV were also negative.

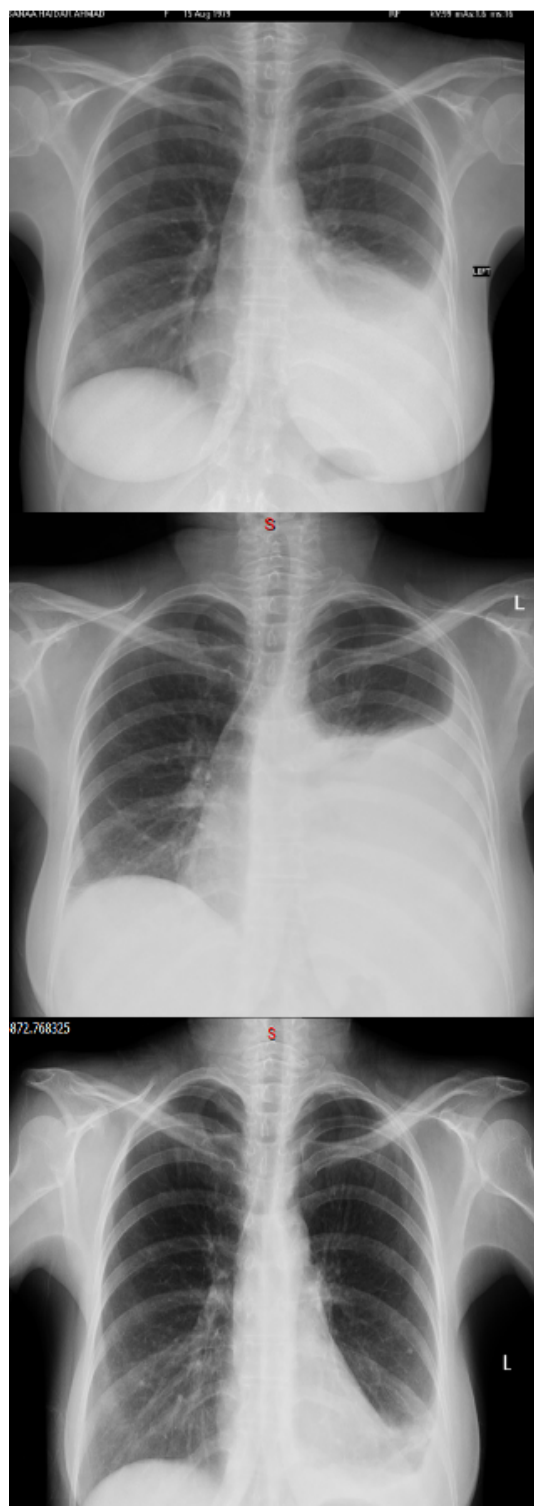


Figure 1. a. Demonstrating the patient's pleural effusion on admission; Figure 1. b. Showing the pleural effusion 7 days after the pleural tap; Figure 1. c. Showing the follow-up chest X-ray done after the initiation of IBD treatment.

Three days after her admission, the patient

developed diarrhea, initially watery, then bloody and mucoidal. The patient was started on ciprofloxacin 400 mf IV every 12

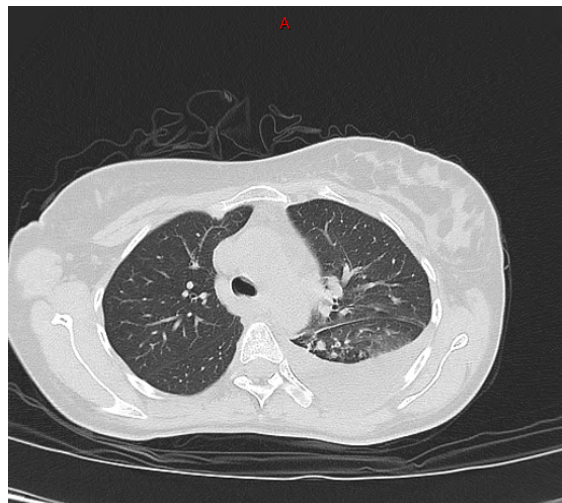


Figure 2: CT angiography of the chest moderate left pleural effusion millimetric nodules, and mild left atelectasis with no signs of pulmonary embolism or lymph node enlargement were visible.

Table 2: Laboratory Findings of Thoracocentesis. LDH: Lactate Dehydrogenase, RBC: Red Blood Cell, WBC: White Blood Cell.

LDH	299 IU/L
Protein	40 g/L
RBCs	940 cells/mm ³
WBCs	1930 cells/mm ³
Lymphocytes	71%
Cholesterol	112 mg/dl
Glucose	58 mg/dL

hours and Flagyl 500 mg IV every 8 hours. Stool analysis was positive for numerous WBCs and RBCs. Stool culture was ordered and turned out to be negative along with *C. difficile* toxins A and B. CT angiography abdomen/pelvis showed mural thickening and spastic deflation in the sigmoid and rectum. These findings go with colitis; thus colonoscopy was performed. A colonoscopy revealed the presence of hyperemic mucosa, edema, erosions, and ulcers: rectosigmoiditis (figure 3). Pathology

confirmed the diagnosis of partially treated ulcerative colitis (cryptitis, crypt abscesses, and chronic inflammation). The patient was put on Solumedrol 20 mg IV every 8 hours and Asacol 4 g per day. A few days later

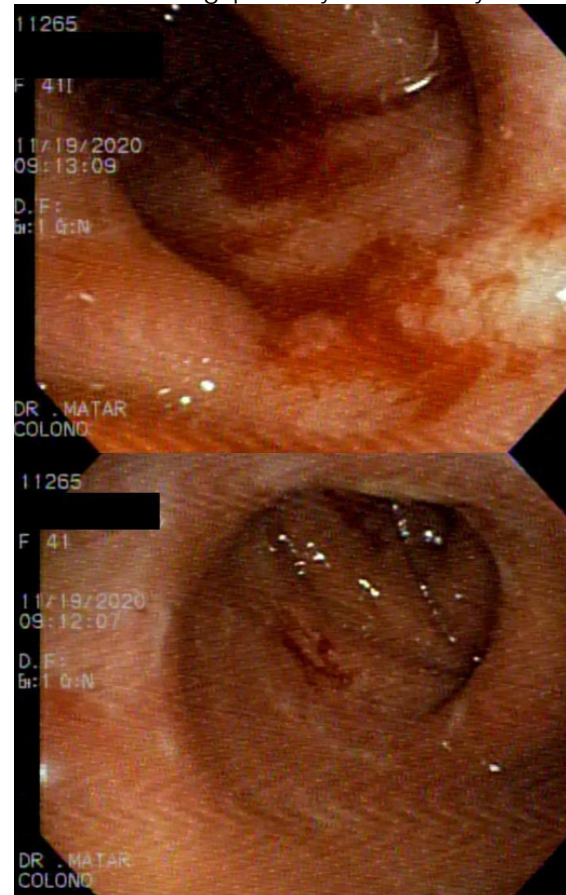


Figure 3: Showing diffuse edematous, hyperemic mucosa with erosions and superficial ulcers on colonoscopy

with the improvement of diarrhea and after discharge home (day 10), chest imaging repeatedly showed total resolution of the pleural effusion without any procedure (figure 1.c). Thus, excluding all the reasons for exudative pleural effusion (pulmonary embolism, pneumonia, malignancy, autoimmune other systemic diseases and infections including tuberculosis), we found that pleural effusion is associated with ulcerative colitis.

Discussion

Lung disease in patients with IBD was first reported in 1976 [14]. Kraft et al. studied six patients with IBD, who developed chronic suppurative sputum, with or without bronchiectasis. Later on, different types of

pulmonary involvement were studied, including interstitial pneumonitis, cryptogenic organizing pneumonia, panbronchiolitis, bronchiolitis obliterans organizing pneumonia (BOOP), inflammatory tracheal stenosis, serositis, pulmonary vasculitis, apical fibrosis, Langerhans cell histiocytosis, sarcoidosis, and conditions resembling Wegener's granulomatosis [5,15]. In general, IBD patients report frequent respiratory symptoms [16]. In contrast, pulmonary involvement remains rare [17,18].

The above-mentioned case presents one of the rare pulmonary manifestations of IBD. Even Though the true mechanism behind these manifestations is not truly known, it is believed that it is due to an inflammatory process. The inflammatory cytokines such as interleukin (IL)-1, IL-2, and IL-6 and tumor necrosis factor (TNF)- α are produced by sensitized immune cells in the bowel tissues; these cytokines increase the production of damaging reactive oxygen metabolites, alter leukocyte migration, and induce damage and inflammation and may be fibrosis of the lung parenchyma [19,20], same can increase mesothelial and capillary permeability of the vasculature of the parietal pleura that can develop excess pleural fluid [21].

For our patient, after diagnosis of exudative pleural effusion with lymphocytic predominance was done, pulmonary embolism and tuberculous serositis were ruled out. No evidence was there to support the diagnosis of pneumonia or another infectious process. After establishing a plausible diagnosis, the patient was put on Asacol and steroids. Imaging (Chest x-ray) after 2 weeks showed resolution of pleural effusion (figure 1.c). This response is supported by studies that showed that most cases of IBD and serositis are very responsive to steroid drugs. Steroid drugs are effective and for the long-term control of large airway pulmonary complications of IBD-related disease [21]. Infliximab is effective in the pulmonary complications of ulcerative colitis [22]. Neither colectomy nor classic nonsteroidal drugs including

immunosuppressants have demonstrated any benefit in the control of the respiratory manifestations of IBD.

Although interstitial lung disease can also be provoked by the administration of certain drugs, such as sulfasalazine, 5-aminosalicylic acid, methotrexate, azathioprine, and anti-TNF drugs [5,19]. Pulmonary complications are present in 80 to 85 percent of patients after the onset of inflammatory bowel disease, present before any activity of bowel disease in 10 to 15 percent, and develop concomitantly in 5 to 10 percent with IBD activity. About 50 % of the patients with airway disease have undergone colectomy for severe UC; in some cases, the development of airway symptoms follows colectomy in days to weeks. The majority of patients with serositis have active inflammatory bowel disease, while parenchymal lung disease presents during inactive bowel disease [4].

Conclusion

As presented above, inflammatory bowel diseases could manifest outside the gastrointestinal system. One of the systems where these manifestations might occur is the respiratory system. In conclusion, pulmonary manifestations of IBD are not uncommon, and can significantly impact a patient's quality of life. Healthcare providers should be aware of the potential pulmonary complications associated with IBD and consider them in their diagnostic and treatment approaches. Further research is needed to better understand the pathophysiology and optimal management of pulmonary manifestations of IBD.

References

1. The Facts About Inflammatory Bowel Diseases. New York, NY: Crohn's and Colitis Foundation of America; 2014. <http://www.crohnscolitisfoundation.org/assets/pdfs/updatedibdfactbook.pdf>
2. Rankin GB. Extraintestinal and systemic manifestations of inflammatory bowel disease. *Med Clin North Am.* 1990;74(1):39-50. [https://doi.org/10.1016/s0025-7125\(16\)30585-5](https://doi.org/10.1016/s0025-7125(16)30585-5). PMID: 2404180
3. Levine JS, Burakoff R. Extraintestinal

- manifestations of inflammatory bowel disease. *Gastroenterol Hepatol (N Y)*. 2011;7(4):235-241. PMID: 21857821
4. Camus P, Piard F, Ashcroft T, Gal AA, Colby TV. The lung in inflammatory bowel disease. *Medicine (Baltimore)*. 1993;72(3):151-183. PMID: 8502168
 5. Black H, Mendoza M, Murin S. Thoracic manifestations of inflammatory bowel disease. *Chest*. 2007;131(2):524-532. <https://doi.org/10.1378/chest.06-1074>. PMID: 17296657
 6. van Lierop PP, Samsom JN, Escher JC, Nieuwenhuis EE. Role of the innate immune system in the pathogenesis of inflammatory bowel disease. *J Pediatr Gastroenterol Nutr*. 2009;48(2):142-151. <https://doi.org/10.1097/mpg.0b013e3181821964>. PMID: 19179875
 7. Higenbottam T, Cochrane GM, Clark TJ, Turner D, Millis R, Seymour W. Bronchial disease in ulcerative colitis. *Thorax*. 1980;35(8):581-585. <https://doi.org/10.1136/thx.35.8.581>. PMID: 7444824
 8. Bonniere P, Wallaert B, Cortot A, et al. Latent pulmonary involvement in Crohn's disease: biological, functional, bronchoalveolar lavage and scintigraphic studies. *Gut*. 1986;27(8):919-925. <https://doi.org/10.1136/gut.27.8.919>. PMID: 3015749
 9. Wallaert, B., Colombel, J. F., Tonnel, A. B., Bonniere, P. H., Cortot, A., Paris, J. C., & Voisin, C. (1985). Evidence of lymphocyte alveolitis in Crohn's disease. *Chest*, 87(3), 363-367. <https://doi.org/10.1378/chest.87.3.363>
 10. Ji XQ, Wang LX, Lu DG. Pulmonary manifestations of inflammatory bowel disease. *World J Gastroenterol*. 2014 Oct 7;20(37):13501-11. <https://doi.org/10.3748%2Fwjg.v20.i37.13501>. PMID: 25309080
 11. Barrecheguren M, Pons J, Trujillo G, et al. Bronchiectasis in ulcerative colitis: a case report. *Respir Med Case Rep*. 2020 Oct 3;31:101296. <https://doi.org/10.1016/j.rmcr.2020.101296>. PMID: 33083374
 12. Li L, Liu P, Niu X, He C. Interstitial Lung Disease as an Extraintestinal Manifestation of Crohn's Disease in the Time of COVID-19: A Rare Case Report and Review of the Literature. *Journal of inflammation research*. <https://doi.org/10.2147/jir.s380879>. PMID: 36238767
 13. Taveras NT, Martinez AR, Kumar R, Jamil A, Kumar B. Pulmonary manifestations of inflammatory bowel disease. *Cureus*. 2021 Mar 31;13(3). <https://doi.org/10.7759%2Fcuri.14216>. PMID: 33948406
 14. Kraft SC, Earle RH, Roesler M, Esterly JR. Unexplained Bronchopulmonary Disease With Inflammatory Bowel Disease. *Arch Intern Med*. 1976;136(4):454-459. PMID: 1267553
 15. Betancourt SL, Palacio D, Jimenez CA, Martinez S, Marom EM. Thoracic manifestations of inflammatory bowel disease. *AJR Am J Roentgenol*. 2011;197(3):W452-W456. <https://doi.org/10.2214/ajr.10.5353>. PMID: 21862772
 16. Douglas, J. G., McDonald, C. F., Leslie, M. J., Gillon, J., Crompton, G. K., & McHardy, G. J. R. (1989). Respiratory impairment in inflammatory bowel disease: does it vary with disease activity? *Respiratory medicine*, 83(5), 389-394. [https://doi.org/10.1016/s0954-6111\(89\)80070-8](https://doi.org/10.1016/s0954-6111(89)80070-8). PMID: 2616823
 17. Loftus EV Jr. Clinical epidemiology of inflammatory bowel disease: incidence, prevalence, and environmental influences. *Gastroenterology*. 2004;126(6):1504-1517. PMID: 15168363. <https://doi.org/10.1053/j.gastro.2004.01.063>
 18. Hoffmann RM, Kruis W. Rare extraintestinal manifestations of inflammatory bowel disease. *Inflamm Bowel Dis*. 2004;10(2):140-147. <https://doi.org/10.1097/00054725-200403000-00013>. PMID: 15168815
 19. Mahadeva R, Walsh G, Flower CD, Shneerson JM. Clinical and radiological characteristics of lung disease in inflammatory bowel disease. *Eur Respir J*. 2000;15(1):41-48. <https://doi.org/10.1183/09031936.00.15104100>. PMID: 10678619
 20. Williams, H., Walker, D., & Orchard, T. R. (2008). Extraintestinal manifestations of inflammatory bowel disease. *Current gastroenterology reports*, 10(6), 597-605. <https://doi.org/10.1007/s11894-008-0108-6>
 21. Kuzniar, T., Sleiman, C., Brugière, O., Groussard, O., Mal, H., Mellot, F., ... & Fournier, M. (2000). Severe tracheobronchial stenosis in a patient with Crohn's disease. *European Respiratory Journal*, 15(1), 209-212. <https://doi.org/10.1399-3003.2000.15a38.x>
 22. Porcel JM. Biomarkers in the diagnosis of pleural diseases: a 2018 update. *Ther Adv Respir Dis*. 2018;12:1753466618808660. <https://doi.org/10.1177/1753466618808660>. PMID: 30354850