

# Manuka Honey Versus Wet to Dry Dressing for Wound Closure Time After Open Pilonidal Sinus Surgery

Houssam Khodor Abtar, MD, FS, FACS<sup>1</sup>, Jad Jamal Terro, MD<sup>2</sup>, Etienne El-Helou, MD<sup>2</sup>, Kassem Mohammad Jammoul, MD<sup>2</sup>, Rayan Said Lakkis, MD<sup>2</sup>, Nathalie Haidar Ismail, MD<sup>2</sup>, Mohammad Ahmad Al-Raishouni, MD<sup>3</sup>, Charbel Joseph Aoun, MD<sup>4</sup>

<sup>1</sup>Department of Surgery, Central Military Hospital, Beirut, Lebanon

<sup>2</sup>General Surgery Department, Faculty of Medical Sciences, Lebanese University, Beirut, Lebanon

<sup>3</sup> FAHS Surgical Services, Michigan, USA

<sup>4</sup>General Surgery Department, Faculty of Medical Sciences, Balamand University, North, Lebanon

Corresponding Author: Jad Jamal Terro, MD. Faculty of Medical Sciences, Lebanese University, Beirut, Lebanon, [j.terro@hotmail.com](mailto:j.terro@hotmail.com)

doi: <https://doi.org/10.38179/ijcr.v3i1.25>

## Abstract:

**Background:** Sacrococcygeal pilonidal sinus disease is a very common chronic inflammation of the natal cleft that presents frequently as an abscess. Management requires the eradication of the sinus tract and postoperative wound care. Manuka honey (Medihoney) was used in acute and chronic wounds. In our study, we sought to investigate the clinical effectiveness of Manuka honey in decreasing wound healing time post excision.

**Material and Methods:** We describe patients' characteristics using traditional descriptive statistics. We compared the study endpoint (wound closure time) in patients who received Medihoney versus those who did not by Kaplan-Meier analysis.

**Results:** A total of 119 patients underwent pilonidal cyst surgery between the years 2017 and 2018. The median time for healing in the Medihoney group was 40 days compared with 39 days in the control group. After adjusting for age, BMI, wound length, wound volume, smoking and operative time, the time to healing in the Medihoney group was significantly less compared to the group not receiving the treatment (Hazard Ratio 1.56, 95% Confidence interval 1.02- 2.49, p= 0.041).

**Conclusion:** Postoperative use of Manuka honey showed a significant decrease in wound healing time when compared to gauze fabric dressings. Further research would be beneficial to explore optimal treatment protocols for this dressing technique.

**Keywords:** *Sacrococcygeal Pilonidal Disease, Open Wound, Manuka Honey, Wet to Dry Dressing.*

Received: 2020.10.18  
Accepted: 2022.03.31  
Published: 2022.08.01

**Financial support:** None  
**Conflict of interest:** None  
**Ethical approval:** Ethical approval for the study was obtained from the Institution Review Board of the faculty of medical sciences of the Lebanese University

## Introduction

Sacroccygeal pilonidal sinus disease (PSD) is mainly seen in young adults predominantly of working age. It is a common chronic inflammation of the natal cleft. Incidence is reportedly 26 per 100,000 population [1]. PSD mainly presents as an abscess or a chronically discharging, painful sinus tract. This can affect normal activity with significant morbidity. The ideal management is a rapid return to normal daily activity with a low risk of complications and morbidity [2].

The therapy of PSD is variable and requires the elimination of the sinus tract, healing of the wound, and most importantly preventing its recurrence. The surgical wound may be left to heal by secondary intention, or by primary intention with either midline closure techniques or off-midline techniques [3].

Most recurrences have been observed to occur within the first year of surgery, however, recurrence over 20 years later has also been observed [4]. Healing by secondary intention reduces recurrence rates by 35% when compared with excision and primary closure of the wound [5]. When primary closure is employed, closure performed off the midline also decreased recurrence [5].

Pilonidal sinus disease recurrence can cause significant morbidity, and sometimes, may require several surgical interventions with continuous wound management. This has led to alternative techniques for the treatment of such chronic cases [6].

One such alternative is the use of the topical honey gel after surgical excision. The literature reports its beneficial use in the treatment of acute or chronic wounds, such as burns [7], wound infections [8], leg ulcers [9,10,11], and Fournier's gangrene [12].

A combination of factors found in topical honey can improve wound healing, including antimicrobial activity, elevated antioxidant levels, a high osmotic activity

that draws exudates from the wound, and a high debriding action because of the present proteolytic enzymes [13]. It also acts as a physical barrier around the wound [14].

Manuka honey is derived from the *Leptospermum* tree species and has wound healing and antimicrobial properties [15]; however, what distinguishes it from other topical honey is that the antimicrobial activity is independent of the presence of hydrogen peroxide which is usually used in lay open wounds and in chronic pilonidal sinuses, and a higher osmolality. The agent identified to provide this additional antibacterial action is methylglyoxal [16].

Around 60 species of bacteria can be inhibited by honey including *Citrobacter freundii*, *Alcaligenes faecalis*, *E. coli*, *Klebsiella pneumoniae*, *Enterobacter aerogenes*, *Staphylococcus aureus*, and *Staphylococcus epidermidis* [17]. It is also reported that Manuka honey has an effect on *Pseudomonas aeruginosa*, *vancomycin-resistant Enterococcus species*, and *methicillin-resistant S. aureus* (MRSA) [18].

Several case series and studies showed the effectiveness of manuka honey in the management of PSD, following incision and drainage [6].

We aimed to investigate the usage of topical Manuka honey gel (Medihoney Wound Gel) in patients with pilonidal disease after excision and its effect on wound healing.

## Material and Methods

Our patients' characteristics have been described using traditional descriptive statistics: continuous variables were explained using means and standard deviation (ex: age, BMI, etc.). Categorical variables were summarized by proportions and percentages (ex: exercise, smoking status, comorbidities...) [Table 1].

Study endpoints for this cohort of patients were wound closure time. We compared the study endpoints between patients who

received Medihoney versus those who did not by Kaplan-Meier analysis [Figure 1] and assessed whether observed differences were significant by the log-rank test [Tables 2 and 3].

**Study design and surgical procedure:** Patients were randomly assigned to the Medihoney group or Wet-To-Dry group. Patients were managed in an academic university hospital with wide excision of the sinus, under spinal anesthesia, in the prone position.

The width, length, and volume of the wounds were measured [Figure 2]. No intravenous or oral antibiotics were given intraoperatively or postoperatively, respectively. Patients in the Manuka honey group were informed to apply ointment inside the wound once daily after irrigating with normal saline. Patients in the other group performed daily wet-to-dry dressing. All patients were followed weekly in the outpatient clinic until complete healing was observed.

In addition, we used a Cox proportional hazards model to obtain adjusted wound closure rates for Medihoney users versus non-users [Table 4]. These models were adjusted for known risk factors for wound closure such as age, BMI, wound length, and wound volume in addition to other clinically relevant factors.

**Results**

119 patients underwent pilonidal cyst surgery between the years 2017 and 2018.

The average age of patients was 25.9 years old, and the average BMI was 27.07. More than two-thirds of patients were smokers (78.6%) and 73.5% reported no history of alcohol consumption. 95.8% of patients had no comorbidities, and 97.5% reported no chronic medication intake [Table 1]. The median time-to-healing in the Medihoney group was 40 days compared with 39 days in the control group that was not receiving the treatment [Figure 3]. The difference was not statistically significant (p= 0.5). After adjusting for age, BMI, wound length,

wound volume, smoking and operative time, the time-to-heal in the Medihoney group was significantly shorter than the control group [Hazard Ratio 1.56, 95% Confidence interval 1.02- 2.49, p= 0.041], In addition, wound volume and wound length were associated with a significantly longer time-to-heal (HR 0.89; 95% CI 0.82- 0.96, p= 0.004) and (HR 0.65; 95% CI 0.46- 0.94; p= 0.02), respectively [Table 4].

**Table 1: Patient Characteristics**

Age	25.92 (6.06)	
BMI	27.08 (3.81)	
Smoking	Yes	92 (78.6%)
	No	25 (21.4%)
Alcohol	Yes	31 (26.5%)
	No	86 (72.3%)
Comorbidities	Yes	5 (4.2%)
	No	113 (95.8%)
Surgery time (min)	13.71 (5.22)	
Wound volume (ml)	6.9 (5.45)	
Wound length (cm)	2.83 (1.17)	

**Discussion**

The management of pilonidal disease presents a difficulty for both the patient and the surgeon. The goal of any management should be to eliminate the disease with the lowest risk, cost, disability, distress, and lowest recurrence rate. Despite the description of multiple surgical and non-surgical treatment methods, ideal management treatment has not yet been established. Complete excision of the sinus tract is usually practiced, but wound management post-excision remains controversial [19].

**Table 2: Means and medians for survival time (CI: Confidence Interval).**

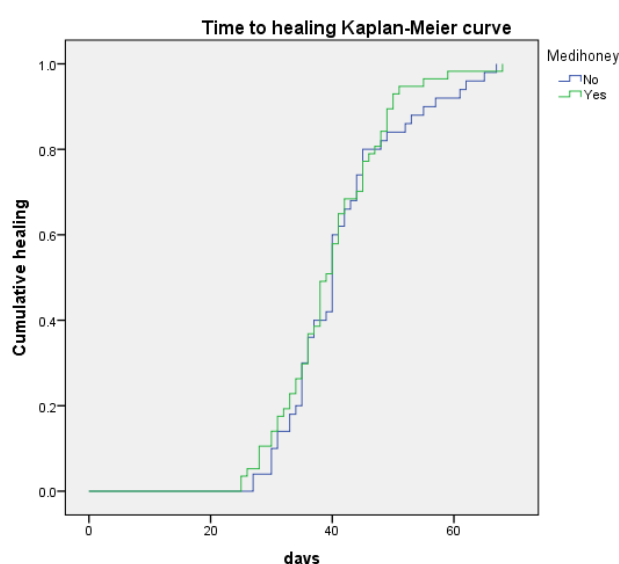
Medihoney	Mean				Median			
	Estimate	Standard Error	95% CI		Estimate	Standard Error	95% CI	
			Lower Bound	Upper Bound			Lower Bound	Upper Bound
No	41.320	1.345	38.684	43.956	40.000	.385	39.246	40.754
Yes	39.772	1.133	37.552	41.992	39.000	1.029	36.982	41.018
Overall	40.495	.870	38.790	42.201	40.000	.679	38.670	41.330

**Table 3: Test of equality of survival distributions for the different levels of Medihoney. (df: degree of freedom, SS: Statistical Significance).**

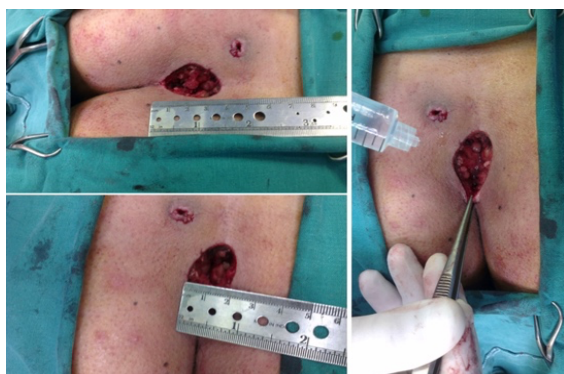	Chi-Square	df	SS
Log Rank (Mantel-Cox)	.401	1	.527

**Table 4: Hazard ratio after adjustment to patient characteristics.**

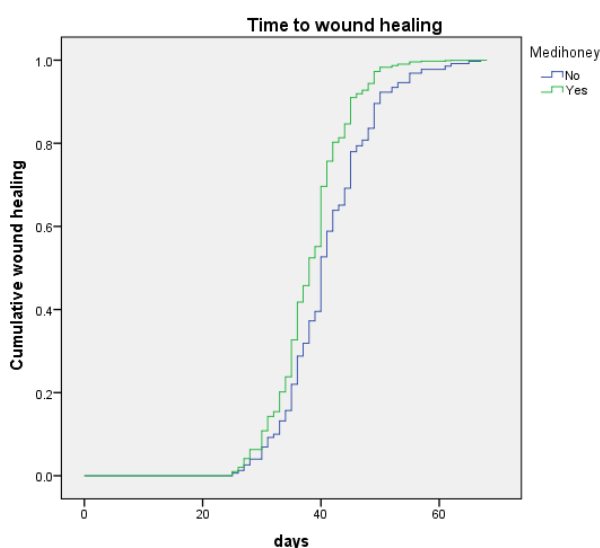
	P-value	Hazard Ratio (HR)	95.0% CI for HR	
			Lower	Upper
Medihoney	0.041	1.593	1.019	2.489
Wound volume	0.004	0.891	0.824	0.963
Wound length	0.022	0.654	0.455	0.940
Age	0.762	1.006	0.970	1.042
BMI	0.179	1.039	0.983	1.099
Smoking	0.207	0.727	0.442	1.193
Operation time	0.600	1.019	0.949	1.095



**Figure 1: Time to healing Kaplan-Meier curve.**



**Figure 2: Intraoperative measurements (length, width and volume).**



**Figure 3: Median time to healing in the Medihoney group compared with the control group.**

Wide excision and packing aim to prevent infectious complications by healing with secondary intention closure [20]. In comparison to healing by primary intention, the low recurrence rate and healing complications of Manuka honey in healing by secondary intention lead to its use as a treatment option for pilonidal disease [5, 21, 22, 23].

Gauze fabric dressings are often routinely used for acute surgical wounds that are left to heal by secondary intention; However, modern dressings (Silastic sponge, alginates, and Aquacel) are easier to apply and less painful when removed. In addition, they have benefits in assisting the healing process [24]. The advantages of Manuka honey (Medihoney) dressings in wound management have been well

documented [13, 14, 15, 16].

The participants in this study tolerated the dressing technique well. Honey is relatively inexpensive when weighed against the expense of recurrent surgery and daily dressing changes with wet gauze.

In a randomized controlled trial [25] pilonidal sinus wounds were left to heal by secondary intention with hydrocolloid dressings. The results showed increased patient comfort, but no change in healing time when compared to gauze alone. The median healing time of hydrocolloid dressings was 65 days compared to 68 days in the control group.

In a randomized double-blind placebo-controlled trial [26], topical zinc oxide dressings were used in PSD wounds. Median healing time was noted to be 54 days when using topical zinc oxide, compared to 62 days in the control group. There was a significant reduction in the use of postoperative antibiotics, however, no statistically significant difference in healing time was noted.

Many studies have shown that Manuka honey dressings effectively shorten the healing time of partial or full-thickness burns [27]. In the present study on pilonidal cysts, the time-to-healing in the Medihoney group was significantly lower than that of the control group not receiving the treatment (Hazard Ratio 1.56, 95% Confidence interval 1.02- 2.49,  $p= 0.041$ ). In addition, wound volume and wound length were associated with a significantly longer time-to-healing. Other variables such as age, BMI, smoking status, and operation duration were not associated with a significant difference in time-to-wound healing.

Study limitation: Our cohort was made of a limited number of patients who were treated in a single institution. All patients were male, in their mid-twenties, with the majority having no comorbidities and in good physical health (average BMI 27.08  $\text{kg/m}^2$ ).



## Conclusion

This study proves the efficiency of Manuka Honey in decreasing the healing time in patients post pilonidal cyst surgical excision. Manuka Honey use is quite simple, fast, painless, and can be administered in the outpatient setting. Thus counting on its beneficence, future prospective research comparing the use of Manuka Honey with other dressing techniques should be implemented to find the best ways to aid PSD patients.

## References

1. Horwood J, Hanratty D, Chandran P, Billings P. Primary closure or rhomboid excision and Limberg flap for the management of primary sacrococcygeal pilonidal disease? A meta-analysis of randomized controlled trials. *Colorectal Dis.* 2012;14(2):143-151. PMID: 20969718 <https://doi.org/10.1111/j.1463-1318.2010.02473.x>
2. McCallum IJ, King PM, Bruce J. Healing by primary closure versus open healing after surgery for pilonidal sinus: systematic review and meta-analysis. *BMJ.* 2008;336(7649):868-871. PMID: 18390914 <https://doi.org/10.1136/bmj.39517.80816.0.BE>
3. Milone M, Velotti N, Manigrasso M, Anoldo P, Milone F, De Palma GD. Long-term follow-up for pilonidal sinus surgery: A review of literature with metanalysis. *Surgeon.* 2018;16(5):315-320. PMID: 29699781. <https://doi.org/10.1016/j.surge.2018.03.009>
4. Doll D, Krueger CM, Schrank S, Dettmann H, Petersen S, Duesel W. Timeline of recurrence after primary and secondary pilonidal sinus surgery. *Dis Colon Rectum.* 2007;50(11):1928-1934. PMID: 17874268. <http://dx.doi.org/10.1007/s10350-007-9031-4>
5. Al-Khamis A, McCallum I, King PM, Bruce J. Healing by primary versus secondary intention after surgical treatment for pilonidal sinus. *Cochrane Database Syst Rev.* 2010;2010(1):CD006213. Published 2010 Jan 20. PMID: 20091589. <https://doi.org/10.1002/14651858.CD006213.pub3>
6. Thomas M, Hamdan M, Hailes S, Walker M. Manuka honey as an effective treatment for chronic pilonidal sinus wounds. *J Wound Care.* 2011;20(11):528-533. PMID: 22240847 <https://doi.org/10.12968/jowc.2011.20.11.528>
7. Subrahmanyam M. Topical application of honey in treatment of burns. *Br J Surg.* 1991;78(4):497-498. PMID: 2032114. <https://doi.org/10.1002/bjs.1800780435>
8. Al-Waili NS, Saloom KY. Effects of topical honey on post-operative wound infections due to gram positive and gram negative bacteria following caesarean sections and hysterectomies. *Eur J Med Res.* 1999;4(3):126-130. PMID: 10085281
9. Gethin G, Cowman S. Case series of use of Manuka honey in leg ulceration. *Int Wound J.* 2005;2(1):10-15. PMID: 16722850 <https://doi.org/10.1111/j.1742-4801.2005.00078.x>
10. Sare JL. Leg ulcer management with topical medical honey. *Br J Community Nurs.* 2008;13(9). PMID: 19024040 <https://doi.org/10.12968/bjcn.2008.13.Su.p4.30930>
11. van der Weyden EA. Treatment of a venous leg ulcer with a honey alginate dressing. *Br J Community Nurs.* 2005;Suppl:S21-S27. PMID: 15944502 <https://doi.org/10.12968/bjcn.2005.10.Su.p2.18175>
12. Hejase MJ, Simonin JE, Bihrlle R, Coogan CL. Genital Fournier's gangrene: experience with 38 patients. *Urology.* 1996;47(5):734-739. PMID: 8650874 [https://doi.org/10.1016/S0090-4295\[96\]80017-3](https://doi.org/10.1016/S0090-4295[96]80017-3)
13. Lay-flurrie K. Honey in wound care: effects, clinical application and patient benefit. *Br J Nurs.* 2008;17(11):S30-S36. PMID: 18773594

<https://doi.org/10.12968/bjon.2008.17.Su.p5.29649>

14. Sharp A. Beneficial effects of honey dressings in wound management. Nurs Stand. 2009;24(7):. PMID: 19927561  
<http://dx.doi.org/10.7748/ns.24.7.66.s54>

15. Molan, P. Why honey is effective as a medicine: 2. The scientific explanation of its effects. Bee world. 2001;82(1).  
<https://doi.org/10.1080/0005772X.2001.11099498>

16. Mavric E, Wittmann S, Barth G, Henle T. Identification and quantification of methylglyoxal as the dominant antibacterial constituent of Manuka (Leptospermum scoparium) honeys from New Zealand. Mol Nutr Food Res. 2008;52(4):483-489. PMID: 18210383  
<https://doi.org/10.1002/mnfr.200700282>

17. Aggad, H., & Guemour, D. Honey antibacterial activity. Med. Arom. Plants. 2014;3.  
<http://dx.doi.org/10.4172/2167-0412.1000152>

18. Boateng J, Diunase KN. Comparing the Antibacterial and Functional Properties of Cameroonian and Manuka Honeys for Potential Wound Healing-Have We Come Full Cycle in Dealing with Antibiotic Resistance?. Molecules. 2015;20(9):16068-16084. Published 2015 Sep 2. doi:10.3390/molecules200916068. PMID: 26364634  
<https://doi.org/10.3390/molecules200916068>

19. STALEY CA. Colon and Rectal Surgery, 4th edition. Ann Surg. 2001;234(6):814.

20. Hull TL, Wu J. Pilonidal disease. Surg Clin North Am. 2002;82(6):1169-1185. PMID: 12516846.  
[https://doi.org/10.1016/s0039-6109\(02\)00062-2](https://doi.org/10.1016/s0039-6109(02)00062-2)

21. Lesalniaks I, Fürst A, Rentsch M, Jauch KW. Erhöhtes Rezidivrisiko nach primärem medianem Wundverschluss bei Patienten mit Pilonidalsinus [Primary midline closure after excision of a pilonidal sinus is associated with a high recurrence rate]. Chirurg. 2003;74(5):461-

468. PMID: 12748795.

<https://doi.org/10.1007/s00104-003-0616-8>

22. Bascom J, Bascom T. Failed pilonidal surgery: new paradigm and new operation leading to cures. Arch Surg. 2002;137(10):1146-1151. PMID: 12361421.

<https://doi.org/10.1001/archsurg.137.10.1146>

23. Kronborg O, Christensen K, Zimmermann-Nielsen C. Chronic pilonidal disease: a randomized trial with a complete 3-year follow-up. Br J Surg. 1985;72(4):303-304. PMID: 3886069  
<https://doi.org/10.1002/bjs.1800720418>

24. Bethell E. Why gauze dressings should not be the first choice to manage most acute surgical cavity wounds. J Wound Care. PMID: 12838602. 2003;12(6):237-239.

<https://doi.org/10.12968/jowc.2003.12.6.26503>

25. Agren MS, Ostenfeld U, Kallehave F, et al. A randomized, double-blind, placebo-controlled multicenter trial evaluating topical zinc oxide for acute open wounds following pilonidal disease excision. Wound Repair Regen. 2006;14(5):526-535. PMID: 17014663

<https://doi.org/10.1111/j.1743-6109.2006.00159.x>

26. Viciano V, Castera JE, Medrano J, et al. Effect of hydrocolloid dressings on healing by second intention after excision of pilonidal sinus. Eur J Surg. 2000;166(3):229-232. PMID: 10755338

<https://doi.org/10.1080/110241500750009339>

27. Al-Waili N, Salom K, Al-Ghamdi AA. Honey for wound healing, ulcers, and burns; data supporting its use in clinical practice. ScientificWorldJournal. 2011;11:766-787. Published 2011 Apr 5. PMID: 21479349

<https://doi.org/10.1100/tsw.2011.78>