

Lyme Borreliosis Associated with Sensorineural Hearing Loss: A Case Report

Obey Albaini^{1*}, Georges Abikanaan^{2*}, Alain Sabri³

¹Department of Clinical Research, Lebanese American University Medical Center, Beirut, Lebanon

²Department of Otolaryngology, Head and Neck Surgery, Lebanese American University Medical Center, Beirut, Lebanon

³Department of Otolaryngology, Head and Neck Surgery, Sheikh Shakhbout Medical City, Abu Dhabi, United Arab Emirates

Corresponding Author: Alain Sabri, Abu Dhabi, United Arab Emirates, alainsabri@yahoo.com

This case was reported from the Department of Otolaryngology, Head and Neck Surgery, Lebanese American University Medical Center, Beirut, Lebanon

*Authors contributed equally to this article

doi: <https://doi.org/10.38179/ijcr.v2i1.68>

Abstract

Background: Lyme borreliosis is a tick-borne infection caused by *Borrelia* species. It has a geographic distribution that makes it more frequent in certain regions like North America and Europe. It manifests in a wide range of symptoms but is often under-investigated in patients presenting with sensorineural hearing loss (SNHL).

Case Report: In this report, we describe a case presenting with SNHL as a manifestation of neuroborreliosis in a female adult patient suffering from Lyme disease, with multiple metachronous symptoms, including arthritis and seizures. Lyme borreliosis (LB) was clinically diagnosed and supported by positive serologic tests, along with Babesiosis. The patient was treated with intravenous (IV) ceftriaxone and azithromycin, in addition to oral atovaquone. Improvement after 4 weeks of treatment was noted in all aspects, including SNHL and arthritis.

Conclusion: LB is a possible, but rare, etiology of hearing impairment. It has been documented that if treatment is initiated early, improvement and even complete recovery are possible. Hence, in a patient presenting with SNHL and a high index of suspicion for LB, assessment for LB is warranted.

Keywords: Sensorineural hearing loss; Lyme borreliosis; *Borrelia burgdorferi*; Neuroborreliosis; Case report.

Received: 2021.02.22
Accepted: 2021.04.10
Published: 2021.05.31

Financial support: None
Conflict of interest: None
Patient Consent:
Patient's written consent for the publication of this case and images was taken.

Background

The most commonly used definition of sudden sensorineural hearing loss (SSNHL) is postulated by the National Institute for Deafness and Communication Disorders (NICDC), defining this condition as an acute idiopathic hearing loss of 30 dB or more that occurs within less than 72 hours over at least three test frequencies with no clear underlying condition identifiable by history or examination [1]. This definition was also adopted for the 2019 American Academy of Otolaryngology-Head and Neck Surgery (AAO-HNS) practice guidelines [2].

The incidence of SSNHL cannot be exactly determined due to the spontaneous complete recovery in most patients who do not seek medical consultation. However, a review of literature roughly estimates the incidence to a wide range; ranging from 11 to 77 per 100,000 Americans annually [3]. Evaluation of etiological factors leads to an identifiable cause in only 29% of cases, thus the underlying condition in the majority of patients remains uncertain [4].

The significance of detecting a primary disease at the origin of this manifestation is the possibility to offer a targeted treatment that might have a remarkable effect on the recovery process, as in the case of Lyme borreliosis. Consequently, an evaluation of SSNHL should be conducted based on a focused history and physical examination, along with audiometric testing to confirm the initial diagnosis and to follow up on changes after treatment [5]. Laboratory studies should be based on findings from history or physical examination suggestive of a specific etiology, such as Lyme borreliosis in patients coming from endemic areas [2].

Lyme borreliosis (LB) is a tick-borne infection caused by the spirochete *Borrelia* species, which is transmitted by infected *Ixodes* ticks [6]. The incidence of Lyme borreliosis varies from one region to another. It is most prevalent in North America and Europe [7], but it is an

extremely rare condition in Lebanon, as literature never reported a case of LB being acquired in this country. However, different *Ixodes* species have been described to be present between southern Turkey and northern Syria [8], and a single case of Lyme disease was reported in northern Iraq, next to the described geographic region [9]. Moreover, only 75 cases of Lyme disease were described in 36 different reports in Turkey [10], suggesting that undetected or unreported cases might have existed in Lebanon as well.

Clinically, the disease is divided into three stages: early localized (Stage 1), early disseminated (Stage 2), and late Lyme disease (Stage 3). Stage 1 usually appears one month after the tick bite and is characterized by a specific skin lesion called erythema migrans. Several weeks, even months, after the infection, Stage 2 disease presents with cutaneous, cardiac, and neurologic manifestations. Among the neurologic features of early disseminated Lyme disease is cranial nerve neuropathy [11]. The most commonly affected cranial nerve is the facial nerve (cranial nerve VII), causing peripheral unilateral or bilateral facial paralysis. In addition, other cranial nerves can be affected, including cranial nerve VIII, provoking hearing loss with or without vestibular symptoms [12]. Even though arthritis is the most common symptom of Stage 3 Lyme disease, neurologic features, including subtle encephalopathy, polyneuropathy, or cranial neuropathies, can also occur, including cranial nerve VIII injury [11].

Serologic testing provides support to the clinical diagnosis of Lyme borreliosis; however, antibodies to *Borrelia burgdorferi* should be considered only as an adjunct to the clinical diagnosis, since, by itself, serologic testing can neither establish nor exclude the diagnosis of Lyme borreliosis [13]. If the patient has neurologic features, testing of cerebrospinal fluid using polymerase chain reaction (PCR) would be a diagnostic tool [14].

Concerning the value of routine testing for *Borrelia* serology in the case of SNHL,

studies have shown that 16% of patients with SNHL were seropositive for *Borrelia*. However, the general population already has a 13.5% seropositivity rate [15].

Regarding treatment options for patients with early disseminated disease presenting with facial nerve palsy, the recommended regimen is 2 to 4 weeks of oral doxycycline, with no added benefit for the use of adjunctive therapy, mainly glucocorticoids [16]. The same treatment applies for patients with affected cranial nerve VIII due to LB [17]. When patients have additional neurologic manifestations and cannot take oral doxycycline, parenteral antibiotic therapy based on IV ceftriaxone is a valid option that should be considered as the first alternative option [18]. In patients with late Lyme neuroborreliosis, IV ceftriaxone, cefotaxime, or penicillin G are usually recommended for a typical therapy duration of 4 weeks [19].

Case Presentation

This is the case of a 21-year-old Lebanese female living in Los Angeles, who presented to our clinic in December 2019 for sensorineural hearing loss post Lyme borreliosis.

During a visit to Utrecht in the Netherlands in July 2018, our patient had severe flu-like symptoms and a rash in the form of a bull's eye. She did not recall being bitten by a tick and did not use any medication except for symptomatic treatment. A month later, she was involved in a motor vehicle accident where she experienced head trauma. Physical assessment at that time, in addition to imaging, showed no abnormalities. In October 2018, she started to exhibit symptoms of confusion, memory loss, and fever. She also experienced repetitive seizure episodes confirmed on EEG. C-Reactive Protein (CPR) level was in the normal range at 2.2 mg/L, and blood and cerebrospinal fluid cultures were negative. Human Immunodeficiency Virus (HIV) and Tuberculin skin tests turned out negative as well. A delayed concussion syndrome

was thought to be the primary diagnosis responsible for the displayed symptoms. With normal imaging studies and unremarkable neurology and neurosurgery consults, a watchful waiting approach was chosen. The seizures were classified as provoked tonic-clonic seizures, and the patient was started on a 200 mg daily dose of carbamazepine for 6 months. No more seizures were later reported.

In January 2019, she became highly irritable and impulsive with generalized anxiety symptoms. A psychiatrist recommended the use of fluoxetine 20 mg daily, which she took for 6 weeks. She reported that her symptoms worsened after the use of the selective serotonin reuptake inhibitor (SSRI).

A month later, she presented to another hospital in Lebanon, where the diagnosis of Lyme Borreliosis was suspected based on her travel history and symptoms. During this time, the patient developed arthritis in her knees, hip, shoulders, metacarpophalangeal joints, and proximal and distal interphalangeal joints. Blood and CSF samples were sent to Germany to be studied, and she was started on ceftriaxone 1 gram daily through an intravenous (IV) line, for a total of 3 weeks. Meanwhile, antibodies against *Borrelia* were detected on ELISA in both her serum and CSF. The presence of IgG antibodies against *Borrelia* was confirmed by Western blot, but IgM antibodies were absent. Titer levels were not reported as the tests were mainly qualitative.

Later in March 2019, she presented to a hospital in New York where the workup of Lyme disease was again positive for neuroborreliosis, and Babesiosis was also diagnosed. It is worth mentioning that Babesiosis and Lyme disease can occur as a co-infection because *Ixodes scapularis* ticks don't only transmit *Borrelia burgdorferi*, but also *Babesia microti* [20]. She received IV ceftriaxone for 4 weeks, in addition to IV azithromycin and oral Atovaquone for Babesiosis.

Her symptoms started resolving, including

her arthritis and irritability.

However, during the course of the disease, little attention was paid to her hearing loss. She was unable to recall the onset of her hearing loss and SNHL had not been documented prior to presentation to our clinic for this complaint in December 2019. At the Lebanese American University Medical Center (LAUMC) in Beirut, Lebanon, an audiogram was performed, showing decreased hearing in both ears, as depicted in Figure 1. There was a mild, sloping to moderately severe, sensorineural hearing loss, with excellent Word Recognition Score (WRS) in the left ear. However, in the right ear, there was a moderately severe, sloping-to-severe sensorineural hearing loss, with good WRS.

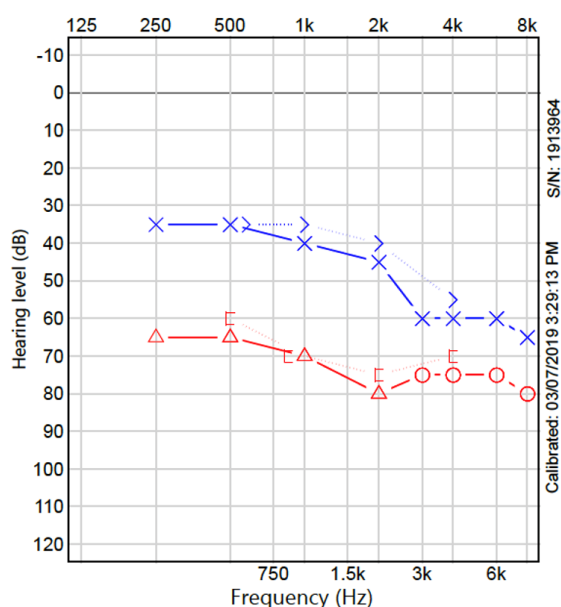


Figure 1: Audiometry to evaluate hearing loss. Findings: Left ear: Mild, sloping to moderately-severe, sensorineural hearing loss, with excellent Word Recognition Score (WRS). Right ear: Moderately-severe, sloping-to-severe sensorineural hearing loss, with good WRS.

We did not know if her SNHL was worse prior to treatment with IV ceftriaxone in Lebanon and then in the United States, as this was not investigated. However, with follow-up on audiogram in the United States, she had mild SNHL in both ears.

Discussion

Sensorineural hearing loss post-Lyme

disease has already been previously described in the literature. In one case report, a patient presented for unilateral hearing loss with vertigo and tinnitus. She was started on corticosteroids and hyperbaric oxygen to avoid treatment delays. Meanwhile, according to the protocol pre-set by the institution for SNHL, Lyme disease was investigated, though no other symptoms of LB were reported. The patient experienced partial recovery on corticosteroids, and full recovery with oral antibiotics, given that corticosteroids have no role in the treatment of LB. She received a daily dose of 200 mg of doxycycline for a total of 2 weeks [6]. Several other case reports attributed SNHL to LB. One stated that hearing loss in the left ear developed 5 years after the primary presentation of erythema migrans. Although the patient received intravenous ceftriaxone, her unilateral SNHL did not improve [21]. In another case, SNHL was diagnosed 1 to 2 years after the onset of atypical symptoms, which were later linked to LB. The patient received ceftriaxone for 8 weeks followed by doxycycline for 3 weeks, after which her hearing loss improved but did not return to normal [22]. In a third article, the patient also did not experience erythema migrans, but suspicion of LB as a cause of SNHL was based on the fact that the patient developed right-sided labyrinthitis, then a month later, she developed facial nerve paresis along with left-sided SNHL. Thus, she was treated with intravenous ceftriaxone for 14 days, but a cochlear implant in the left ear was ultimately required [23].

Our patient received similar treatment to that described in the literature, but it was delayed. The onset of SNHL in the reported cases of LB varied from being very late to being the sole presentation. However, in our case, the patient suffered several symptoms that made her lose track of her hearing loss. Additionally, the first documented decreased hearing was more than a year after the onset of symptoms. Her hearing improved but never returned to its normal baseline, similar to what the

literature described in various cases.

Our patient had a normal CRP level upon initial presentation. This can be explained by the fact that the spirochetes that cause Lyme disease have migrated from the skin towards extracutaneous organs, and thus a decline in CRP level occurred. It is important to note that CRP levels are mainly higher in initial infection with cutaneous manifestations [24]. In addition, blood cultures could not detect the disease because *Borrelia burgdorferi* needs a special medium to grow on, namely Barbour-Stoener-Kelly (BSK) medium [25]. However, even if proper media are used, sensitivity in early untreated disease is reported to be 45%, and a specific polymerase chain reaction (PCR) test is needed for improvement in sensitivity [26]. Similarly, cerebrospinal fluid culture sensitivity for Lyme neuroborreliosis can range between 10 and 30% [27]. These explain why the initial diagnostic approach failed in detecting LB.

The diagnosis was established using a two-tier conditional strategy, starting with an enzyme immunoassay (EIA) followed by a confirmatory Western blot [28]. In our reported case, IgM was negative while IgG was positive in both the serum and the CSF, which pointed to the fact that the disease onset was not new [29].

Patients with suspected central nervous system Lyme disease should have their CSF tested for antibodies against *B. burgdorferi*. However, IgG antibodies against *B. burgdorferi* can remain present in the CSF for years after treatment, so the establishment of active neuroborreliosis necessitates the presence of other inflammatory markers in the CSF like pleocytosis or increased protein level [30].

Lyme borreliosis is typically a clinical diagnosis. The role of serological testing for *Borrelia* is used only to support the diagnosis. According to the literature, 20% to 40% of patients in early-stage disease are seropositive for *Borrelia burgdorferi* [31]. The overall frequency found in the literature of positive serological findings for

LB in patients with SNHL reached up to 21.3% [21], making this diagnosis an important etiology that should always be taken into consideration. Nevertheless, serologic testing for *Borrelia* serology in areas that are not pandemic for Lyme borreliosis was shown to be cost-ineffective [32]. Patients with positive IgM antibodies had a higher prevalence of low-frequency hearing loss compared to those with IgG antibodies, and their response to antibiotics was more favorable [33]. This would further support the notion to not only assess for LB in patients presenting with SNHL, but also to assess for SNHL in those newly diagnosed with LB. IgM antibodies against *Borrelia burgdorferi* are usually positive in the first few weeks post-infection, after which IgG antibodies start to be detected [29].

LB should be on the differential diagnosis in patients who present with SNHL with a travel history suggestive of exposure, given that the disease has a geographic distribution [34, 35]. In the reported case, the patient already had confirmed neuroborreliosis with SNHL upon presentation. Her history was negative for the use of other ototoxic drugs, and her presentation was not suggestive of autoimmune disorders or other diseases like Ménière's disease or multiple sclerosis, all of which can cause SNHL. Though she had a brain concussion, her brain imaging results were negative for any anatomical brain cause, including trauma and tumors.

Certain viruses or bacteria can cause viral cochleitis, leading to SNHL [36]. HIV and tuberculosis infections were both ruled out in our patient. Cytomegalovirus (CMV) on the other hand is usually associated with hearing problems in infants in case of congenital infection [37], but CMV infection with such severe symptoms is rare in immunocompetent adults like our patient [38]. Varicella-Zoster Virus can cause Ramsay Hunt Syndrome, but the latter usually presents with a triad of ipsilateral facial nerve palsy, ear pain with or without decreased hearing, and vesicles on the auricle [39]. This triad was absent in our patient. Similarly, symptoms of mumps,

measles, rubella, or *Mycoplasma pneumoniae* infection were all absent.

Our patient presented with Stage 3 Lyme disease, given that she used to suffer from arthritis, although Stages 2 and 3 can both present with neurological symptoms, including cranial nerve impairment [19]. Even though facial nerve palsy is the most common cranial nerve affected in cases of LB, other nerves can also be affected. Cranial nerve VIII involvement leads to SNHL, as reported in the literature and our case [40]. Usually, unilateral SNHL in Lyme borreliosis occurs suddenly in Stage 2 [21], while bilateral SNHL occurs more gradually and in Stage 3 [22]. Our patient had bilateral SNHL, yet it is unknown if her hearing loss was of sudden or gradual onset. In addition, cranial nerve VIII involvement can cause peripheral vertigo, which was already reported to be a manifestation of Lyme borreliosis [17]. However, our patient did not develop other vestibular manifestations besides SNHL.

Our patient's severe presentation of Lyme borreliosis was most likely the cause behind ignoring her SNHL. In addition, her overall LB diagnosis was late, even though she had a suggestive travel and symptomatic history.

The goal for early identification of LB is to allow for faster initiation of treatment to ensure a better chance of recovery [41]. The treatment of hearing impairment and facial nerve palsy in the context of Lyme disease is similar [42]. Short-term oral antibiotics are recommended due to a lack of evidence supporting long-term regimens, which can be a harmful practice [43]. Outcomes after a full course of antibiotics in reported SNHL cases due to LB are encouraging, and categorize Lyme borreliosis as a potentially treatable etiology of SNHL [44–46].

Arthritis in Lyme disease should be treated with oral amoxicillin or doxycycline for 4 weeks. If symptoms persist or if neurological symptoms are present, intravenous ceftriaxone can be used for 2 to 4 weeks. Carditis is usually treated with

oral amoxicillin or doxycycline for 2 to 3 weeks, but also cefuroxime can be used for the same duration [42]. Using ceftriaxone, our patient was covered for these symptoms.

Audiometric evaluation should be done as part of follow-up at the conclusion of treatment, as well as within 6 months of treatment [47]. However, our patient did not have the chance to perform timely audiometry because SNHL was diagnosed post-treatment.

Conclusion

LB is a possible, but rare, etiology of hearing impairment. It has been documented that if treatment is initiated early, improvement and even complete recovery is possible. Hence, in a patient presenting with SNHL and a high index of suspicion for LB, assessment for LB is warranted.

References

1. US National Institute for Deafness and Communication Disorders [Internet]. Available from: www.nidcd.nih.gov/health/sudden-deafness
2. Chandrasekhar S. Clinical Practice Guideline: Sudden Hearing Loss (Update) [Internet]. Otolaryngol Head and Neck Surg; 2019. Available from: <https://www.entnet.org/content/clinical-practice-guideline-sudden-hearing-loss-update-2019>
3. Alexander TH, Harris JP. Incidence of sudden sensorineural hearing loss. *Otol Neurotol*. 2013;34(9):1586-1589. PMID: 24232060. <https://doi.org/10.1097/mao.000000000000022>
4. Chau JK, Lin JR, Atashband S, Irvine RA, Westerberg BD. Systematic review of the evidence for the etiology of adult sudden sensorineural hearing loss. *Laryngoscope*. 2010;120(5):1011-1021. PMID: 20422698. <https://doi.org/10.1002/lary.20873>
5. Slattery WH, Fisher LM, Iqbal Z, Liu N. Oral steroid regimens for idiopathic sudden sensorineural hearing loss. *Otolaryngol Head Neck Surg*. 2005;132(1):5-10. PMID: 15632902. <https://doi.org/10.1016/j.otohns.2005.03.001>

04.09.072

6. Espiney Amaro C, Montalvão P, Huins C, Saraiva J. Lyme disease: sudden hearing loss as the sole presentation. *J Laryngol Otol*. 2015;129(2):183-186. PMID: 25619547. <https://doi.org/10.1017/s0022215114003417>
7. Lorenzi MC, Bittar RS, Pedalini ME, et al. Sudden deafness and Lyme disease. *Laryngoscope*. 2003;113(2):312-315. PMID: 12567088. <https://doi.org/10.1097/00005537-200302000-00021>
8. Aydin L, Bakirci S. Geographical distribution of ticks in Turkey. *Parasitol Res*. 2007;101 Suppl 2:S163-S166. PMID: 17823820. <https://doi.org/10.1007/s00436-007-0694-5>
9. Fisher JB, Curtis CE. An unexpected case of Lyme disease in a soldier serving in northern Iraq. *Mil Med*. 2010;175(5):367-369. PMID: 20486511. <https://doi.org/10.7205/milmed-d-09-00079>
10. Önal U, Aytaç Erdem H, Uyan Önal A, Reşat Sipahi O. Systematic review of Lyme disease in Turkey. *Trop Doct*. 2019;49(3):165-170. PMID: 31018773. <https://doi.org/10.1177/0049475519843387>
11. Steere AC, Strle F, Wormser GP, et al. Lyme borreliosis. *Nat Rev Dis Primers*. 2016;2:16090. PMID: 27976670. <https://doi.org/10.1038/nrdp.2016.90>
12. Koedel U, Pfister HW. Lyme neuroborreliosis. *Curr Opin Infect Dis*. 2017;30(1):101-107. PMID: 27820708. <https://doi.org/10.1097/qco.0000000000000332>
13. Hu LT. In the clinic. Lyme disease. *Ann Intern Med*. 2012;157(3):ITC2-2-ITC2-16. PMID: 22868858. <https://doi.org/10.7326/0003-4819-157-3-201208070-01002>
14. Agüero-Rosenfeld ME, Wang G, Schwartz I, Wormser GP. Diagnosis of Lyme borreliosis. *Clin Microbiol Rev*. 2005;18(3):484-509. PMID: 16020686. <https://doi.org/10.1128/cmr.18.3.484-509.2005>
15. Bakker R, Aarts MC, van der Heijden GJ, Rovers MM. No evidence for the diagnostic value of Borrelia serology in patients with sudden hearing loss. *Otolaryngol Head Neck Surg*. 2012;146(4):539-543. PMID: 22394551. <https://doi.org/10.1177/0194599811432535>
16. Nadelman RB, Luger SW, Frank E, Wisniewski M, et al. Comparison of cefuroxime axetil and doxycycline in the treatment of early Lyme disease. *Ann Intern Med*. 1992;117(4):273-280. PMID: 1637021. <https://doi.org/10.7326/0003-4819-117-4-273>
17. Jozefowicz-Korczynska M, Zamysłowska-Szmytke E, Piekarska A, Rosiak O. Vertigo and Severe Balance Instability as Symptoms of Lyme Disease-Literature Review and Case Report. *Front Neurol*. 2019;10:1172. PMID: 31798513. <https://doi.org/10.3389/fneur.2019.01172>
18. Halperin JJ, Shapiro ED, Logigian E, et al. Practice parameter: treatment of nervous system Lyme disease (an evidence-based review): report of the Quality Standards Subcommittee of the American Academy of Neurology. *Neurology*. 2007;69(1):91-102. PMID: 17522387. <https://doi.org/10.1212/01.wnl.0000265517.66976.28>
19. Wormser GP, Dattwyler RJ, Shapiro ED, et al. The clinical assessment, treatment, and prevention of Lyme disease, human granulocytic anaplasmosis, and babesiosis: clinical practice guidelines by the Infectious Diseases Society of America. *Clin Infect Dis*. 2006;43(9):1089-1134. PMID: 17029130. <https://doi.org/10.1086/508667>
20. Wormser GP, McKenna D, Scavarda C, et al. Co-infections in Persons with Early Lyme Disease, New York, USA. *Emerg Infect Dis*. 2019;25(4):748-752. PMID: 30882316. <https://doi.org/10.3201/eid2504.181509>
21. Peeters N, van der Kolk BY, Thijsen SF, Colnot DR. Lyme disease associated with sudden sensorineural hearing loss: case report and literature review. *Otol Neurotol*. 2013;34(5):832-837. PMID: 23303170. <https://doi.org/10.1097/mao.0b013e31827c9f93>
22. Bertholon P, Cazorla C, Carricajo A, Oletski A, Laurent B. Bilateral sensorineural hearing loss and cerebellar ataxia in the case of late stage Lyme disease. *Braz J Otorhinolaryngol*. 2012;78(6):124. PMID: 23306581. <https://doi.org/10.5935/1808-8694.20120046>
23. Vos FI, Merkus P, van Nieuwkerk EB, Hensen EF. Rare cause of bilateral sudden deafness. *BMJ Case Rep*. 2016;2016:bcr2016216004. PMID: 28049117. <https://doi.org/10.1136/bcr-2016-216004>

24. Uhde M, Ajamian M, Li X, Wormser GP, Marques A, Alaedini A. Expression of C-Reactive Protein and Serum Amyloid A in Early to Late Manifestations of Lyme Disease. *Clin Infect Dis*. 2016;63(11):1399-1404. PMID: 27585799. <https://doi.org/10.1093/cid/ciw599>
25. Waddell LA, Greig J, Mascarenhas M, Harding S, Lindsay R, Ogden N. The Accuracy of Diagnostic Tests for Lyme Disease in Humans, A Systematic Review and Meta-Analysis of North American Research. *PLoS One*. 2016;11(12):e0168613. PMID: 28002488. <https://doi.org/10.1371/journal.pone.0168613>
26. Liveris D, Schwartz I, Bittker S, et al. Improving the yield of blood cultures from patients with early Lyme disease. *J Clin Microbiol*. 2011;49(6):2166-2168. PMID: 21490189. <https://doi.org/10.1128/jcm.00350-11>
27. Henningsson AJ, Christiansson M, Tjernberg I, Löfgren S, Matussek A. Laboratory diagnosis of Lyme neuroborreliosis: a comparison of three CSF anti-Borrelia antibody assays. *Eur J Clin Microbiol Infect Dis*. 2014;33(5):797-803. PMID: 24263552. <https://doi.org/10.1007/s10096-013-2014-6>
28. Centers for Disease Control and Prevention (CDC). Recommendations for test performance and in-terpretation from the Second National Conference on Serologic Diagnosis of Lyme Disease. *MMWR Morb Mortal Wkly Rep*. 1995;44(31):590-1.
29. Dressler F, Whalen JA, Reinhardt BN, Steere AC. Western blotting in the serodiagnosis of Lyme disease. *J Infect Dis*. 1993;167(2):392-400. PMID: 8380611. <https://doi.org/10.1093/infdis/167.2.392>
30. Hammers-Berggren S, Hansen K, Lebech AM, Karlsson M. Borrelia burgdorferi-specific intrathecal antibody production in neuroborreliosis: a follow-up study. *Neurology*. 1993;43(1):169-175. PMID: 8423881. https://doi.org/10.1212/wnl.43.1_part_1.169
31. Steere AC, McHugh G, Damle N, Sikand VK. Prospective study of serologic tests for lyme disease. *Clin Infect Dis*. 2008;47(2):188-195. PMID: 18532885. <https://doi.org/10.1086/589242>
32. Richardson H, Birchall JP, Hill J, McMaster T. Should we routinely screen for Lyme disease in patients with asymmetrical hearing loss?. *Br J Audiol*. 1994;28(2):59-61. PMID: 7841889. <https://doi.org/10.3109/03005369409077915>
33. Walther LE, Hentschel H, Oehme A, et al. [Lyme disease--a reason for sudden sensorineural hearing loss and vestibular neuronitis?]. *Laryngorhinootologie*. 2003;82(4):249-257. PMID: 12717599. <https://doi.org/10.1055/s-2003-38938>
34. Estrada-Peña A, Cutler S, Potkonjak A, et al. An updated meta-analysis of the distribution and prevalence of Borrelia burgdorferi s.l. in ticks in Europe. *Int J Health Geogr*. 2018;17(1):41. PMID: 30514310. <https://doi.org/10.1186/s12942-018-0163-7>
35. Maniu A, Damian L. Rapid progressive bilateral hearing loss due to granulomatous otitis media in Lyme disease. *Am J Otolaryngol*. 2013;34(3):245-247. PMID: 23313123. <https://doi.org/10.1016/j.amjoto.2012.11.009>
36. Schattner A, Halperin D, Wolf D, Zimhony O. Enteroviruses and sudden deafness. *CMAJ*. 2003;168(11):1421-1423. PMID: 12771071.
37. Park A, Doutre S, Schleiss MR, Shoup A. All Cytomegalovirus-infected Children Need Hearing and Neurologic Follow-up. *Clin Infect Dis*. 2020;70(1):173. PMID: 31090913. <https://doi.org/10.1093/cid/ciz399>
38. Eddleston M, Peacock S, Juniper M, Warrell DA. Severe cytomegalovirus infection in immunocompetent patients. *Clin Infect Dis*. 1997 Jan;24(1):52-6. PMID: 8994755. <https://doi.org/10.1093/clinids/24.1.52>
39. Crouch AE, Andaloro C. Ramsay Hunt Syndrome. In: StatPearls. Treasure Island (FL): StatPearls Publishing; September 27, 2020. <http://www.ncbi.nlm.nih.gov/books/nbk557409/>
40. Centers for Disease Control and Prevention (CDC). Lyme disease--United States, 2003-2005. *MMWR Morb Mortal Wkly Rep*. 2007;56(23):573-576. PMID: 17568368.
41. Luft BJ, Dattwyler RJ, Johnson RC, et al. Azithromycin compared with amoxicillin in the treatment of erythema migrans. A double-blind, randomized, controlled trial. *Ann Intern Med*. 1996;124(9):785-791. PMID: 8610947. <https://doi.org/10.7326/0003-4819-124-9-199605010-00002>
42. Sanchez E, Vannier E, Wormser GP, Hu LT. Diagnosis, Treatment, and Prevention of Lyme Disease, Human Granulocytic Anaplasmosis, and Babesiosis: A Review. *JAMA*.

2016;315(16):1767-1777. PMID:
27115378.https://doi.org/10.1001/jama.2016.
2884

43. Halperin JJ. Diagnosis and management of
Lyme neuroborreliosis. Expert Rev Anti Infect
Ther. 2018;16(1):5-11. PMID:
29278020.https://doi.org/10.1080/14787210.2
018.1417836

44. Quinn SJ, Boucher BJ, Booth JB.
Reversible sensorineural hearing loss in Lyme
disease. J Laryngol Otol. 1997;111(6):562-564.
PMID: 9231093.
https://doi.org/10.1017/s0022215100137910

45. Mehler K, Emmel M, Petereit HF, et al.
[Sensorineural loss of hearing in lower registers
as the main symptom of Lyme disease]. HNO.
2007;55(12):961-963. PMID: 17103202.
https://doi.org/10.1007/s00106-006-1490-8

46. Huda S, Wieshmann UC. Protracted
neuroborreliosis--an unusual cause of
encephalomyelitis. BMJ Case Rep.
2012;2012:bcr1120115206. PMID:
22665558.https://doi.org/10.1136/bcr.11.2011
.5206

47. Chandrasekhar SS, Tsai Do BS, Schwartz
SR, et al. Clinical Practice Guideline: Sudden
Hearing Loss (Update) Executive Summary.
Otolaryngol Head Neck Surg. 2019;161(2):195-
210. PMID:
31369349.https://doi.org/10.1177/019459981
9859883